

# Medullary Carcinoma of Breast: A Rare Case Study

Dr. Arvind Kumar Prabhat<sup>1</sup>, Dr. Niranjana Dash<sup>2</sup>, Dr. J.M. Gadekar<sup>3</sup>, Dr. Mrs. V.J.Thipse<sup>4</sup>

<sup>1</sup>Postgraduate Student, <sup>2</sup>Professor, <sup>3</sup>Professor and Head of Department, <sup>4</sup>Professor

Department of General Surgery, DVVPF'S Medical College and Hospital, Ahmednagar, Maharashtra, India

**Abstract:-**Medullary breast carcinoma (MBC) is a uncommon variant of invasive ductal carcinoma of breast. It accounts for 4% of all invasive breast cancers and is a frequent phenotype of BRCA 1 hereditary breast cancer. Last five years of our hospital records show only one case of medullary breast carcinoma. Despite of its aggressive histopathological features, it has good prognosis. We report a 38 year female who presented to our hospital with a single, large, well circumscribed lump in the upper outer quadrant of right breast since 3 months. Mammography showed multiple asymmetric densities in upper outer quadrant of right breast. Trucut biopsy report was suggestive of high grade duct carcinoma. She underwent Modified Radical Mastectomy of right breast along with Chemotherapy and Radiotherapy. During 36 month month of follow-up, patient is free of disease. Histopathological report was suggestive of Medullary breast carcinoma. Molecular subtype was Her-2 type i.e: Her-2 neu positive and negative Estrogen receptor (ER) & Progesterone receptor (PR).

**Keywords:** Breast lump, Immunohistochemistry, : Medullary Breast Carcinoma

## I. INTRODUCTION

Typical Medullary breast carcinoma (MBC) and Atypical Medullary breast carcinoma (AMBC) are uncommon variants of Invasive Ductal Carcinoma with BRCA 1 mutation, that account for 4% of Invasive Breast Carcinoma. Bilaterality is reported in 20% of cases.<sup>(1)</sup>

In 1977, the diagnostic criteria of MBC is proposed by Ridolfi et al.<sup>(2)</sup> Despite of its aggressive histopathological features, it has good prognosis. AMBC differs from MBC in terms of histological features with an infiltrative margin, low grade, mild mononuclear infiltration and presence of an intraductal component.<sup>(3)</sup>

In our case, a 37 year old, female with Typical Medullary Carcinoma of right breast was managed successfully by Modified Radical Mastectomy alongwith Chemotherapy and Radiotherapy.

Histopathological features of MBC has specific characteristics such as Syncytial growth pattern, Lymphoplasmacytic infiltrate, minimal or absent ductal differentiation, which help in reaching at final diagnosis and better management of the patient.<sup>(4)</sup>

## II. CASE REPORT

A 37-year-old female patient, presented to the surgical department in DVVPF's Medical college and Hospital with complaints of right breast lump since 3 months. In the last 20 days there was rapid increase in the size of lump. On physical examination it had an ulcero-proliferative lump, located in upper outer quadrant of right breast measuring 7x6x5 cm, which was firm in consistency, well circumscribed and fixed to the skin (Fig.2). No history of any discharge from the nipple. Her family members had no any associated malignancies like breast or ovarian carcinoma. Lump was not fixed to the chest wall. An anterior axillary lymph node measuring 2x2 cm was palpable. On the above clinical findings, patient was staged IIIA [T<sub>3</sub>N<sub>1</sub>M<sub>0</sub>]. Mammogram of right breast revealed asymmetric densities in upper outer quadrant (Fig.3). Mammogram of opposite breast was normal. Radiological examination of chest, abdomen and pelvis showed no evidence of metastasis. FNAC report revealed a highly cellular smear with large tumor cells and poorly cohesive cells arranged in clusters, prominent with pleomorphic nucleoli, in the background many plasma cells and lymphocytes were also seen, which were suggestive of high grade Duct Carcinoma.

All routine investigations were normal. Pre anaesthetic checkup was done and patient was taken up for Modified Radical Mastectomy. Mastectomy specimen was sent for histopathological examination and Immunohistochemistry. The immediate postoperative period was uneventful. Romovac drain was removed after 5 days and skin sutures on the 12<sup>th</sup> postoperative day. The patient was subsequently sent for Chemotherapy and Radiotherapy.

Post-operatively, six cycles of chemotherapy with Adriamycin, Cyclophosphamide and 5-FU, followed by 16 cycles of Radiotherapy were given.

During the follow-up visit, the operative scar was found to be well healed and the patient was absolutely asymptomatic.

### III. HISTOPATHOLOGY REPORT

Gross: Mastectomy specimen labelled as breast tissue measuring about 16x12x6.5 cm along with skin, nipple, and areola, lump of 7x6x5 cm and lymph nodes along with fat.

C/S – Shows whitish well circumscribed area of diameter 3cm, firm in consistency. Lateral cuts shows hemorrhagic areas along with diffuse growth, tumor is 1 cm away from base. Three lymph nodes of size 2x2 cm are identified.

#### Microscopic Examination:

- (1) Section from the nipple and areola shows stratified squamous epithelial lining underneath lobules and acini and fibrocollagenous tissue. No evidence of tumor infiltration.
- (2) Section from tumor shows round to oval cells with ill defined cell borders, hyperchromatic nuclei. The borders are pushing. No evidence of gland formation seen. Syncytial arrangement seen at places. Stroma shows dense lymphocytic infiltrate.
- (3) Section from base shows only fibrofatty tissue. No evidence of tumor infiltration.
- (4) Lymph Nodes: Out of 3 lymph nodes 1 lymph node shows tumor infiltration.

Immunohistochemistry: Her-2 type i.e : Her-2 neu positive and ER,PR negative (Fig.4)

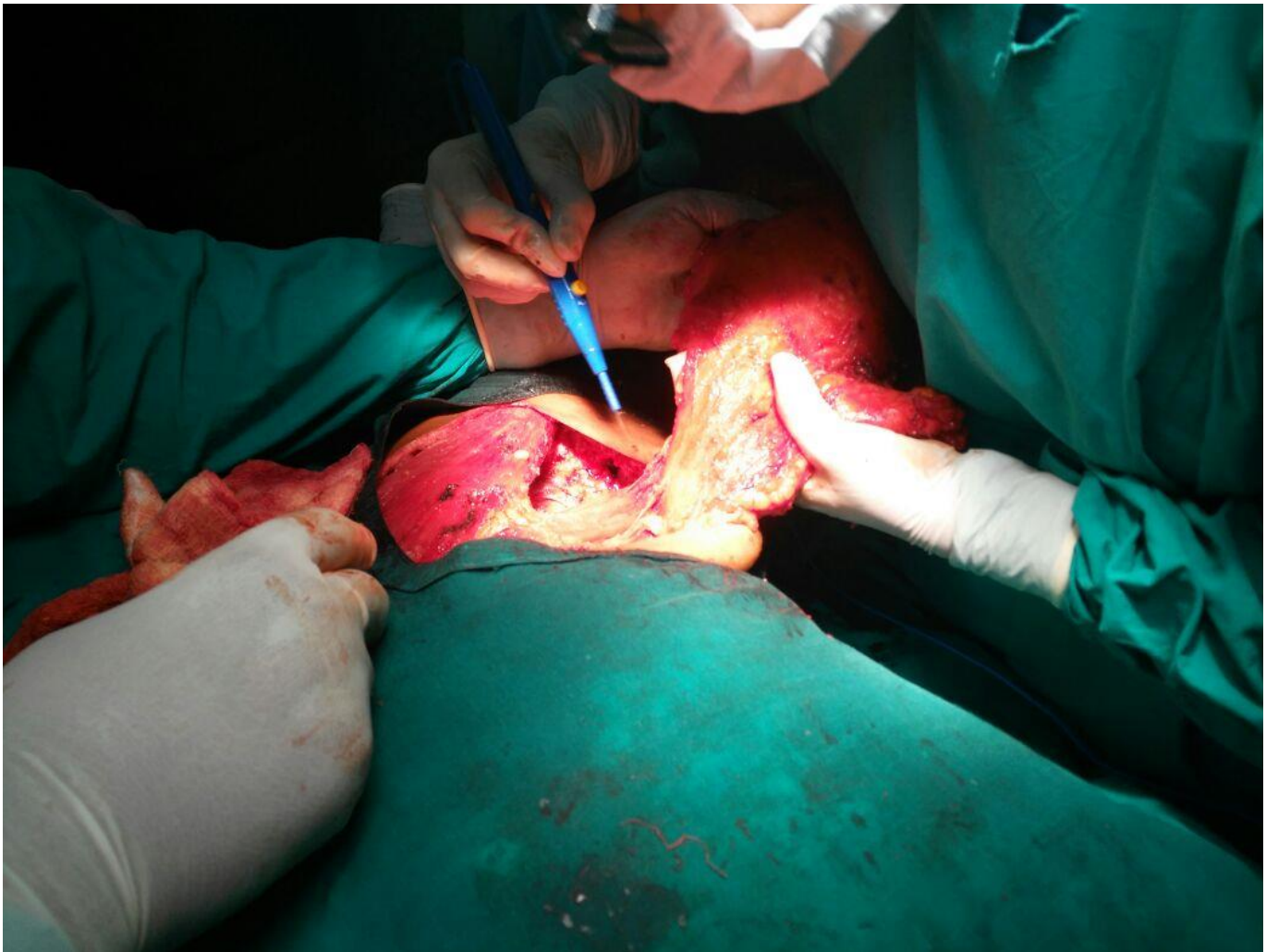


Figure 1: Excision of Breast Lump with Breast Tissue

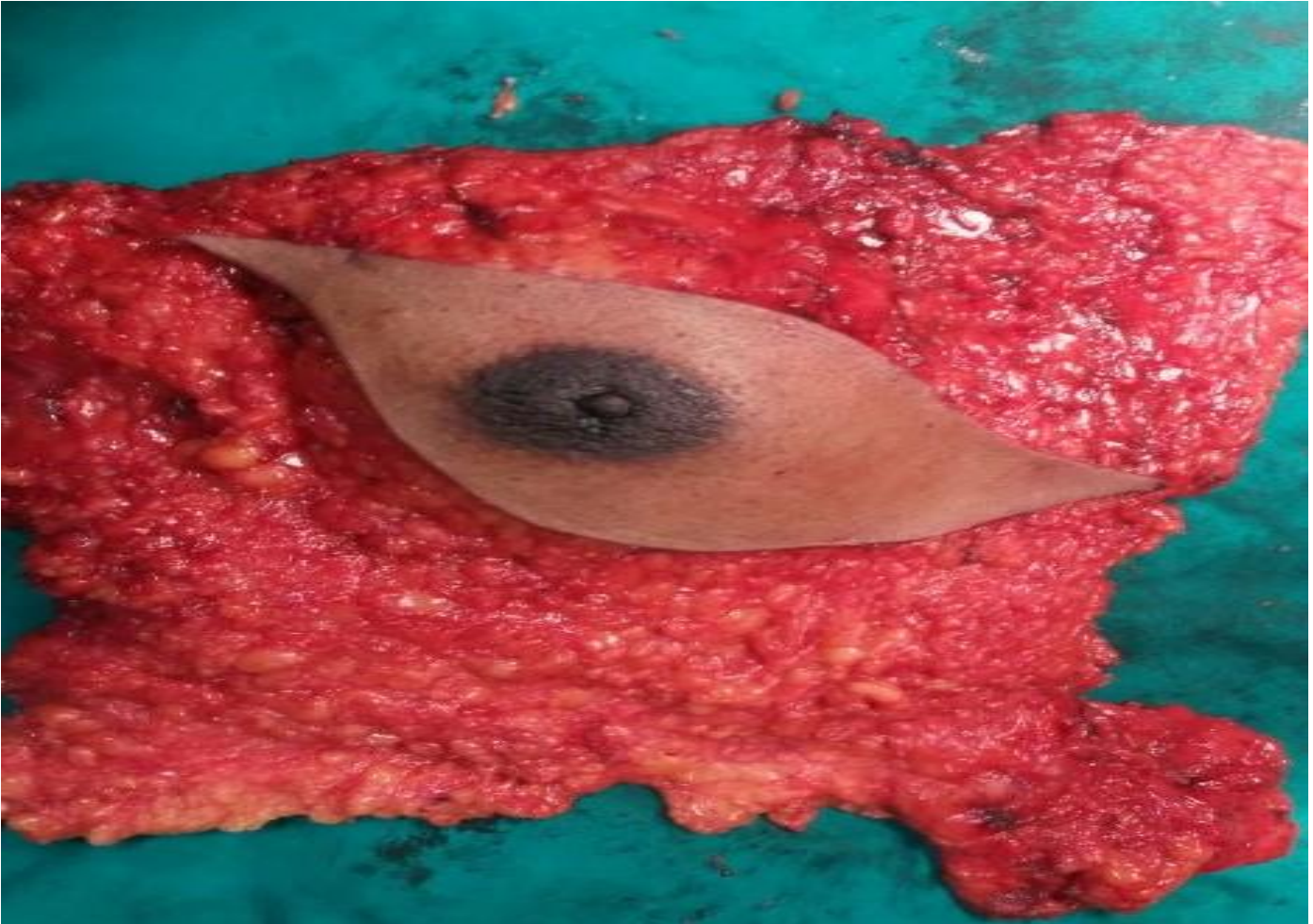


Fig.2: Gross Specimen

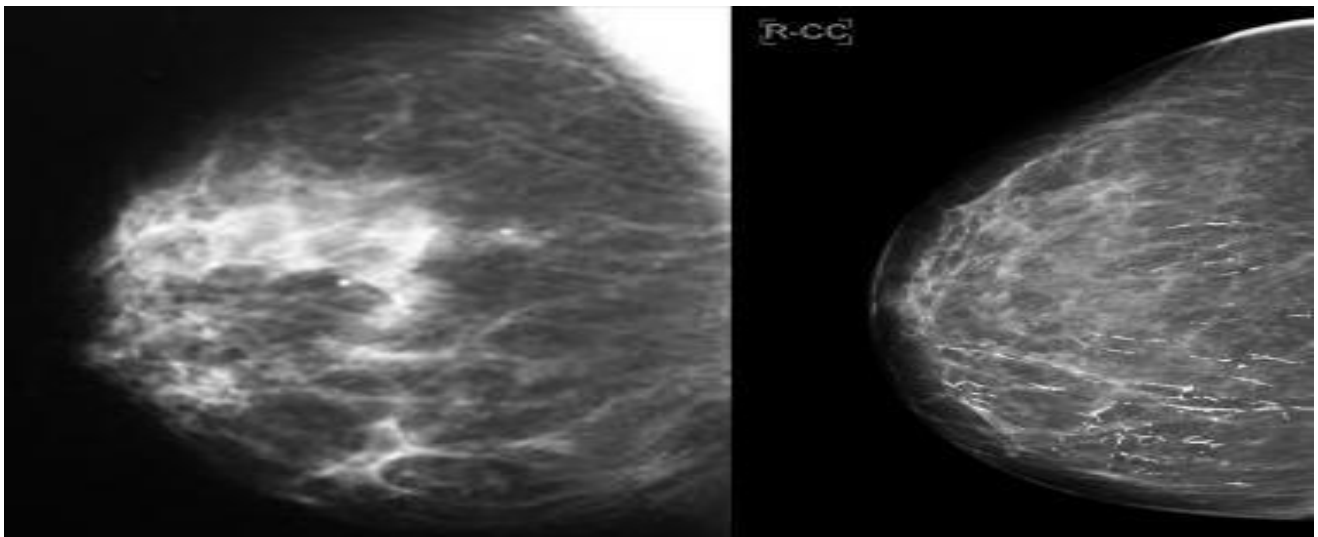


Fig.3: Craniocaudal Mammograms of Right Breast Reveal Asymmetric Densities

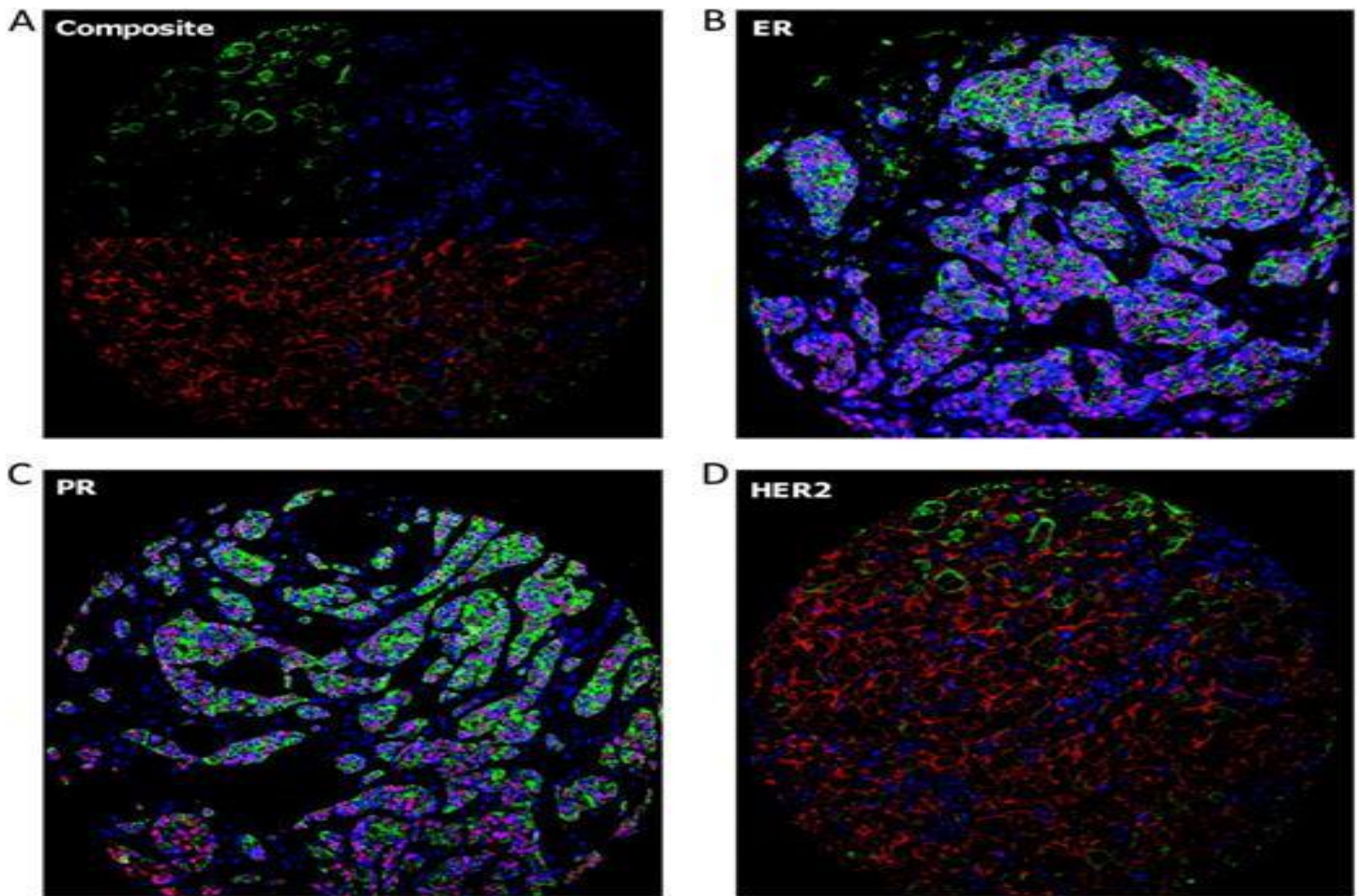


Fig 4: Immunohistochemistry: Her-2 NEU Type i.e. Her-2 NEU Positive and ER,PR Negative

#### IV. DISCUSSION

Breast cancer is the leading cause of death from cancer for women aged 20 to 59 years. It accounts for 29% of all newly diagnosed cancers in females and is responsible for 14% of the cancer-related deaths.<sup>(5)</sup>

MBC accounts for 4% of all invasive breast carcinoma(IBC).<sup>(6)</sup> It usually affects patients under 50 years old and is more common in those have a BRCA 1 mutation.<sup>(7,8)</sup> Due to necrosis and hemorrhage,there is rapid increase in size of breast lump. In our case the right breast lump rapidly increased in the last 20 days of disease course.

On palpation, it is bulky and deep seated within the breast tissue. In our case the lump was also deep seated within the right breast. 80% of MBC are present in single breast. In our case ulceroproliferative lump was located in upper outer quadrant of right breast. The histological diagnostic criteria of MBC is proposed by Ridolfi et al.,

Wargotz and Silverberg<sup>(9)</sup> and Pedersen et al.<sup>(10)</sup> All these three classification systems recognize the following attributes of MBC : (a) A dense infiltration of lymphocytes and plasma cells; (b) Presence of pleomorphic nuclei showing active mitosis; and (c) Growth pattern is sheet- like (d) No ductal or alveolar differentiation. All these microscopic findings were present in our case. 50% of MBC are associated with DCIS and hormone receptors(ER/PR/HER-2-NEU) are present in < 10% of MBC.<sup>(11)</sup> The 5-year survival rate in women with this cancer is 78% with positive lymph nodes and >90% in those with negative lymph nodes.<sup>(12)</sup>

MBC typically express CK7, often S-100 & Vimentin but not CK20.<sup>(13)</sup> In our case it was Her-2 neu positive and ER,PR negative.

MBC does not grow and spread quickly because of extensive presence of Plasma cells and Lymphocytes<sup>(14)</sup> because of which it has good prognosis.

In our case the MBC of right breast was managed by Modified Radical Mastectomy along with Chemotherapy and Radiotherapy. During 36 months of follow-up, patient is free of disease.

## V. CONCLUSION

Medullary breast carcinoma is a rare subtype of Invasive Ductal Carcinoma. Despite its aggressive histopathological features, it has good prognosis. Histopathological features of MBC have specific characteristics which help in reaching at final diagnosis and better management of the patient. MBC is usually misdiagnosed clinically and grossly with Fibroadenoma.

## VI. ETHICAL APPROVAL

Written informed consent was obtained from the patient for publication of this case report.

## REFERENCES

- [1]. V M J Sherman and F C Brunicardi, "The Breast," in *Schwartz's Principles of Surgery*, McGraw-Hill, New York, NY, USA, 2015 ;10: 521-22.
- [2]. Ridolfi RL, Rosen PP, Port A, Kinne D, Miké V. Medullary carcinoma of the breast: a clinicopathologic study with 10 year follow-up. *Cancer*,1977;40:1365-1385.
- [3]. Rosen PP Medullary Carcinoma. In *Rosen™ Breast Pathology*. Lippincott Williams & Wilkins, Philadelphia, 2009;3:449-466.
- [4]. Rosen PP; Medullary Carcinoma. In *Rosen's Breast Pathology*. Lippincott Williams & Wilkins, Philadelphia, 2001;2: 405- 422.
- [5]. V. M. J. Sherman and F. C. Brunicardi, "The Breast," in *Schwartz's Principles of Surgery*, McGraw-Hill, New York, NY, USA, 2015 ;10: 517-518.
- [6]. Dendale R, Vincent-Salomon A, Mouret-Fourme E, Savignoni A, Medioni J, et al. Medullary breast carcinoma: prognostic implications of p53 expression. *Int J Biol Markers*,2003; 18: 99-105.
- [7]. Samir SM ,Fayaz MS, Elbasmi A, Motavuy MM, Albuzallouf S, George T, et al .Medullary carcinoma of the breast :ten year clinical experience of the Kuwait cancer control centre. *Gulf J oncology*,2011;1(10):45-52.
- [8]. Batori M, Ruggier M, Chatelou E, Straniers A, Mariotta G, Palombi L, et al. Breast cancer in young women: case report and a review. *Eur rev Med pharmacol Sci* 2006;10(2):51-52.
- [9]. Wargotz ES, Silverberg SG Medullary carcinoma of the breast: a clinicopathologic study with appraisal of current diagnostic criteria. *HumPathol*,1998;19:1340-1346.
- [10]. Pedersen L, Holck S, Schiodt T Medullary carcinoma of the breast. *Cancer Treat Rev*,1998;15: 53-63.
- [11]. Basu S, Chen W, Tchou J, Mavi A Comparison of triple-negative and Estrogen receptor-positive/progesterone receptor-positive/ HER2-negative breast carcinoma using quantitative fluorine-18 fluorodeoxyglucose/positron emission tomography imaging parameters: a potentially useful method for disease characterization. *Cancer*,2008;112: 995-1000.
- [12]. Reinfuss M, Stelmach A, Mitus J, et al. Typical Medullary carcinoma of the breast: a clinical and pathological analysis of 52 cases. *J Surg. Oncol.* 1995;60(2): 89-94.
- [13]. Eichhorn JH Medullary carcinoma, provocative now as then. *SeminDiagnPathol*, 2004; 21: 65-73.
- [14]. Kuroda H, Tamaru J, Sakamoto G, Ohnisi K, Itoyama S Immunophenotype of lymphocytic infiltration in medullary carcinoma of the breast. *Virchows Arch*, 2005; 446: 10-14.