

# Management of Symptomatic, Discoloured Upper Anteriors through a Combination of Bleaching Techniques: A Case Report

Dr. Deepak Joby, Dr. Princy Paul, Dr. K. Radhakrishnan Nair, Dr. Amal Devadas, Dr. Praveena G

Department of Conservative Dentistry & Endodontics, Azeezia College of Dental Sciences and Research, Kollam, Kerala, India

## Abstract:-

### ➤ Background

**Bleaching of non-vital teeth is the most conservative approach to have a suitable aesthetic result for endodontically treated teeth. Three techniques used for bleaching are: the walking bleach technique, the inside/outside bleach technique, and the in-office bleaching procedure. Because of its simplicity, safety, and less in office time required, walking bleach is the most used technique. This case report describes the management of a discoloured nonvital upper anterior teeth through a combination of walking bleach and in office bleaching.**

### ➤ Case Description

**A 35-year-old female patient reported to the clinic with severe swelling and pain on the upper anterior teeth since one week and had a previous history of trauma in childhood. On examination, 11 and 21 were tender on percussion, severely discoloured and the radiograph showed periapical lesion in both. Root canal treatment was done followed by walking bleach and thermocatalytic bleaching in both teeth. Review showed good aesthetic results and IOPAR after 18 months showed good periapical healing.**

### ➤ Conclusion

**Root canal treatment followed by nonvital bleaching showed good results both aesthetically and periapically in this case for a severely discoloured tooth.**

## I. INTRODUCTION

Dental trauma occurs in all age groups but more vulnerable group is children. Minor trauma during childhood may go unnoticed and it will lead to chronic infection and loss of vitality eventually. Many patients reports to the clinic after a long time; may be 20-30 years later complaining about pain and discoloration of teeth. Further examination may show a chronic infection which may require endodontic treatment and often a periapical surgery. Endodontic treatment of symptomatic nonvital traumatized teeth may require multiple appointments of intracanal dressing and thorough irrigation protocol. Some cases may show good healing of the periapex after routine endodontic treatment; but some other may show persistence of lesion. Such cases may require periapical surgery.

Tooth discoloration may be intrinsic or extrinsic and it varies in aetiology, appearance, localization and severity. Intrinsic discoloration of the tooth can be caused following trauma, loss of vitality, endodontic treatment, and restorative procedures apart from known local and systemic factors. There are different options to treat discoloured teeth such as restorative procedures, veneers, crown etc. Actually, bleaching of non-vital teeth is a routine conservative approach to have a suitable aesthetic result for endodontically treated teeth. Various methods to bleach non-vital teeth have been proposed. The most accepted method is the walking bleach technique since it is simple, safe, with lower risks and suitable for patients. Non-vital teeth that are extensively discoloured are highly receptive for bleaching techniques. A proper cervical barrier placement and an apical seal is necessary to prevent the percolation of bleaching agents into the peri radicular tissues to avoid undesirable post-operative complications. In some cases walking bleach technique may not produce desirable results. In those cases a combination of bleaching techniques<sup>[1]</sup> like walking bleach followed by in office thermocatalytic bleaching can be used for achieving predictable results.

This case report discusses about the management of a symptomatic discoloured nonvital upper central incisors through a combination of walking bleach and in office bleaching.

## II. CASE REPORT

A 35-year-old female patient reported to the Dept. of Conservative Dentistry and Endodontics with the complaint of discolored upper anterior teeth with a swelling in the same area. Patient has a childhood history of trauma to upper anterior teeth. The change of color to the upper anterior teeth was noted a few months back and swelling was noted a week prior to reporting. Patient had consulted a local dentist recently, after which root canal treatment of the same teeth was initiated. Patient did not find any difference in swelling and pain even after two appointments. Hence, she decided to visit our hospital.

On examination there was diffuse swelling in relation to 11 and 21 region. Patient experienced pain for the last one week and was sharp pricking type and was continuous in nature. Pain got aggravated on having hot food items and also during chewing. Both teeth were tender on percussion

and mobility was within normal limits. Discoloration was present in both teeth where 11 had a darker shade compared to normal and 21 was discolored completely with a bluish-pink hue (fig.1&2). Diagnosis was acute exacerbation of chronic periapical lesion(Phoenix abscess) with severe discoloration. As an initial treatment temporary restoration present in the teeth were removed and pus discharge was noted. Through the canal drainage was attained following which gentle irrigation was done using Sodium Hypochlorite and normal saline and closed dressing was given. Upon recall after one week, she was symptom free and biomechanical preparation was done and Calcium Hydroxide dressing was given which was repeated for one more appointment after a week. The canals were dry after two weeks and obturation was done.

She was recalled two weeks after obturation for bleaching. The coronal Gutta Percha was removed up to 2mm below the cervical margin and GIC barrier was placed in sky slope appearance (fig.3). Sodium perborate mixed with distilled water was placed in the pulp chamber and restored temporarily with intermediate restorative material (IRM) for two weeks (Walking bleach technique). Patient was recalled after two weeks and change in shade was noted. Walking bleach technique was repeated and patient was reviewed two weeks later. Considerable change in shade was noted at cervical and middle thirds but not in the incisal thirds(fig.4) in both the teeth. In office Power bleaching was done on the incisal third using 30% H<sub>2</sub>O<sub>2</sub> ('DASH- In office teeth whitening system'-Philips, USA). Patient was reviewed two weeks later and shade of bleached teeth were matching with adjacent teeth(fig.5). Post endodontic restoration was done using composite in both teeth. Patient was reviewed at 3 months and 18 months(fig.6&7) showed good periapical healing and color stability.

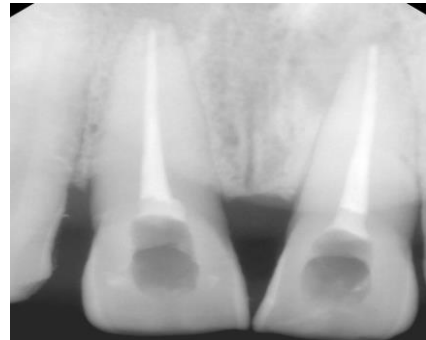

Fig.3: GIC barrier placed in skyslope appearance

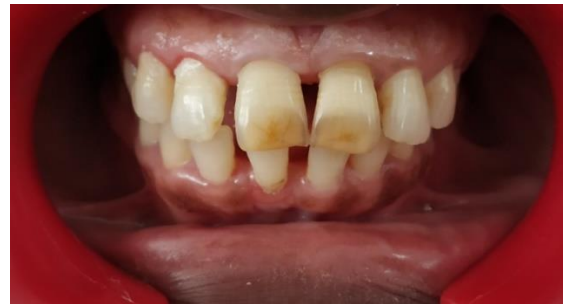

Fig.4: After walking bleach

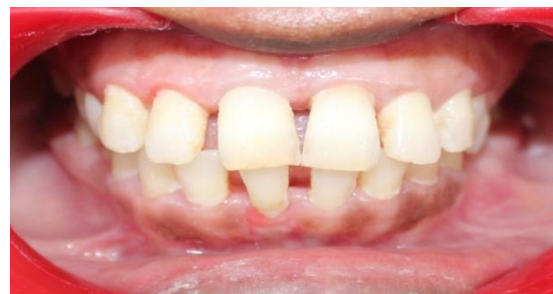

Fig.5: Immediate Post operative picture

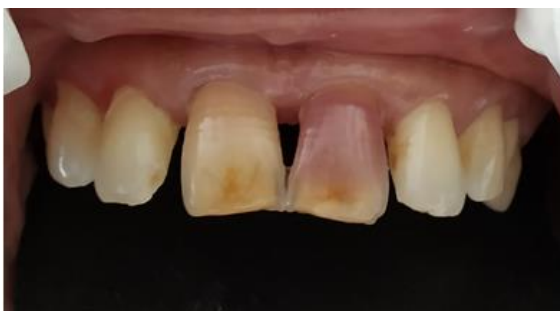

Fig. 1: Preoperative Picture

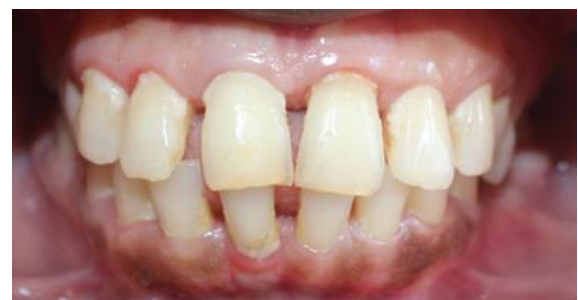

Fig.6: 18 months review

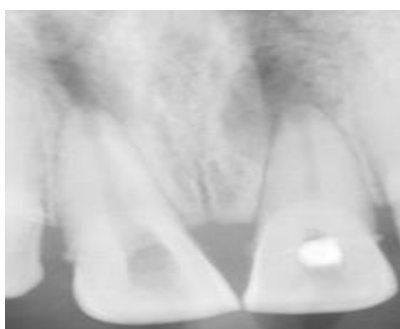

Fig. 2: Preoperative radiograph

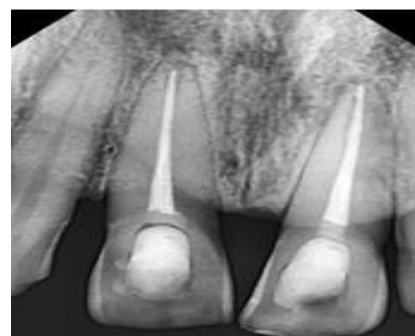


Fig.7:18 months review radiograph

### III. DISCUSSION

Trauma to dental structures may result in fracture of tooth segment. If fracture doesn't occur, force may get dissipated to the pulp and periodontal structures which may cause necrosis of pulpal tissue and periodontal infection in future.<sup>[2,3]</sup> Treatment of dental traumatic injuries without delay is very important in its management. If delayed it may lead to conditions like chronic periapical abscess which may require surgical intervention thus causing patient additional trauma. Proper use of intracanal medicaments will help in reducing infection and thereby achieving sterile environment inside the canal. In this case after 3 weeks of intracanal calcium hydroxide medicament placement, canal was dry suggesting reduction of infection. Because of this reason we planned to go ahead with non-surgical approach of endodontic treatment .

Discoloration of the tooth results from trauma, loss of vitality, endodontic treatment, and restorative procedures. The remnants of the blood stain consequent to trauma or incomplete removal of pulp during endodontic treatment lead to haemolysis.<sup>[4]</sup> The chromogenic blood degradation products, such as hemosiderin, hemin, hematin, and hematoidin, get deposited in the dentinal tubules.<sup>[5]</sup> The accumulated breakdown products lead to greyish-yellow to brown discoloration of the teeth. The discoloured anterior teeth can cause significant aesthetic concerns.

Over the years, a number of bleaching and restorative techniques have been proposed for managing discoloured nonvital incisors. Walking bleach technique is based on the use of chemicals that release active oxygen such as hydrogen peroxide ( $H_2O_2$ ) or sodium perborate (SP). A combination of SP and water or  $H_2O_2$  has been used in the "walking bleach" technique. Walking bleach method was first explained by Spasser which utilizes sodium perborate mixed with distilled water. Sodium perborate when mixed with water releases  $H_2O_2$ . This method was later modified by Nutting and Poe replacing  $H_2O$  with 30%  $H_2O_2$  to improve the effect, but it increased the risk of external cervical root resorption, and hence, is to be used with caution. The pigmentation that causes intrinsic discoloration from necrotic pulp consists of long chain of organic molecule. Bleaching using  $H_2O_2$  oxidizes these long-chain molecules and transform them into carbon while releasing  $H_2O$  and oxygen.<sup>[5]</sup>

Sodium perborate has been widely used to bleach nonvital teeth with predictable results. It is an oxidizing agent containing 95% perborate and is available in three forms: monohydrate, trihydrate, and tetrahydrate. In the presence of water, perborate will break down to form sodium metaborate,  $H_2O_2$ , and oxygen.<sup>[6]</sup> Sodium perborate is also synergistically used with  $H_2O_2$  but when used with water, release of  $H_2O_2$  in a controlled manner with remarkable aesthetic outcome with little or no side effects was noted. The Sodium perborate releases active oxygen radicals inside the pulp chamber and diffuses to the dentinal tubules. It oxidizes and bleaches the iron sulphide and other pigments present in the dentinal tubules and the free radicals

induces oxidative effects to lipids, proteins, and nucleic acids.

In this case after walking bleach procedure, shade change was noted only in cervical and middle third areas. This may be because the bleaching agent was in contact with only the cervical and middle third areas. So power bleaching or thermo catalytic bleaching using 30%  $H_2O_2$  was done on the incisal third. Thermo catalytic techniques use the heat source as a catalyst agent in the decomposition of the whitening agents in oxidizer products. They provide energy to the solution, enabling an easier diffusion on the tooth's surface. Simultaneously, temperature doubles the speed of reaction, achieving thus free oxygen activation; therefore, the whitening procedure is completed in shorter time. When heat and  $H_2O_2$  were used in combination, resorption was induced in a few cases. The mechanism leading to resorption might be that the heat drives the highly caustic  $H_2O_2$  through tubules to chemically alter the cementum, rendering it a foreign substance.<sup>[7]</sup> To avoid this, we used LED light curing unit as heat source instead of a heated device or instrument.

The outcome of the bleaching depends mainly on the concentration of the bleaching agent, ability of the agent to reach the chromophore molecules, and duration and number of times the agent is in contact with chromophore molecules. Although  $H_2O_2$  exhibited excellent aesthetic outcome, the undesirable consequences such as cervical resorption and irreversible damage to the dentin and surrounding tissues led the clinicians to look for alternative methods. Cervical resorption is one of the complications that may occur after bleaching treatment of nonvital teeth. To prevent this, after completion of root canal treatment, GIC barrier was placed at the cervical area in skyslope appearance.<sup>[8]</sup> When the bleaching procedure was completed, the acidic environment in the access cavity should be neutralized by placing calcium hydroxide suspension for 7 days or by using ascorbic acid an antioxidant.<sup>[9]</sup> This duration is necessary to remove excess reactive oxygen in the chamber to provide adequate adhesion to the composite filling material.

### IV. CONCLUSION

Long standing trauma cases may cause severe damage to the pulp and periodontal tissues. Acute exacerbation of such cases are seen commonly where patients present with severe pain and swelling. Achieving good drainage, biomechanical preparation, following ideal irrigation protocols and a fluid tight seal during obturation helps in elimination of the bacterial load in the root canals. For management of discoloured non vital teeth, walking bleach technique is commonly used since it is economical and gives excellent results. In some cases walking bleach alone cannot resolve the discoloration. In those cases a combination of bleaching techniques can be tried which offers predictable results.

**REFERENCES**

- [1]. Izidoro, Ana & Martins, Gislaine & Higashi, Cristian & Zander-Grande, Christiana & Tay, Lidia Yileng & Gomes, João & Campanha, Nara & Jorge, Janaina. Combined Technique for Bleaching Non-Vital Teeth with 6-Month Clinical Follow-Up: Case Report. *International Journal of Oral and Dental Health*. (2015).
- [2]. Andreasen JO, Andreasen FM, Andersson L. Textbook and color atlas of traumatic injuries to the teeth. 4th ed. Oxford: Blackwell Munksgaard; 2007.
- [3]. Huang HM, Tsai CY, Lee HF, Lin CT, Yao WC, Chiu WT et al. Damping effects on the response of maxillary incisor subjected to a traumatic impact force: a nonlinear finite element analysis. *J Dent*. 2006; 34:261-8
- [4]. Plotino G, Buono L, Grande NM, Pameijer CH, Somma F. Nonvital tooth bleaching: a review of the literature and clinical procedures. *J Endod*. 2008 Apr;34(4):394-407.
- [5]. Zimmerli B, Jeger F, Lussi A. Bleaching of nonvital teeth. A clinically relevant literature review. *Schweiz Monatsschr Zahnmed*. 2010;120(4):306-20.
- [6]. Féliz-Matos L, Hernández LM, Abreu N. Dental Bleaching Techniques; Hydrogen-carbamide Peroxides and Light Sources for Activation, an Update. Mini Review Article. *Open Dent J*. 2015
- [7]. Madison S, Walton R. Cervical root resorption following bleaching of endodontically treated teeth. *J Endod*. 1990 Dec;16(12):570-4.
- [8]. Steiner DR, West JD. A method to determine the location and shape of an intracoronal bleach barrier. *J Endod*. 1994;20(6):304–306.
- [9]. Khoroushi M, Saneie T. Post-bleaching application of an antioxidant on dentin bond strength of three dental adhesives. *Dent Res J (Isfahan)*. 2012 Jan;9(1):46-53.