

Tongue Cave: A TAD Supported Customized Habit Breaking Appliance

Shetye SR

(Part III MDS Student)

Department of Orthodontics & Dentofacial Orthopedics
Mahatma Gandhi Dental College & Hospital
Jaipur, India.

Bajaj K

(Professor & Head, MDS.)

Department of Orthodontics & Dentofacial Orthopedics
Mahatma Gandhi Dental College & Hospital
Jaipur, India.

Mittal K

(Reader, MDS.)

Department of Orthodontics & Dentofacial Orthopedics
Mahatma Gandhi Dental College & Hospital
Jaipur, India.

Corresponding author:

Dr. Kimi Mittal

B-2 doctor's flat, Gangwal park, JLN Marg,
SMS Medical college campus.
Jaipur, Rajasthan. Pincode – 302004.

Abstract:- This article showcases a simplified and customized appliance named as 'tongue cave' for tongue thrusting habit with the usage of TADS in the anterior part of the palate. This appliance gives better adaptation and comfort during the wear than the other appliances such as conventional tongue crib, tongue beads and TAD supported tongue crib appliances used before.

Keywords:- Mini implants, tongue crib, tongue cave, habit breaking appliance, tongue trust.

I. INTRODUCTION

As stated by W.H. Tulley, tongue thrust is the forward movement of the tongue tip between the teeth to meet the lower lip in deglutition and in sounds of speech so that the tongue lies interdental¹.

Various appliances have been used to correct tongue thrusting habit such as conventional tongue crib², tongue bead², TAD supported tongue crib³, of which tongue crib is commonly used in practice which has several drawbacks like,

- Patient discomfort
- Indentation of crib over tongue
- Breaking of appliance or appliance fracture at soldered joint
- Bulkiness of appliance

- Difficulty in speech

The previous clinical applications of TAD supported tongue crib appliance can cause discomfort to patients³.

Hence, to overcome this, a new, smooth, customised appliance is fabricated to facilitate the tongue in its new position and break the habit.

This appliance is named as 'tongue cave' due to its cave-like shape, which is simple to fabricate and compliant to the adult patients.

- *Design:*

- Tongue cave has two basic parts in the framework – TADs and an acrylic component.
- TADs are used as a support to the appliance, which will also keep the fabrication as minimal as possible.

II. MATERIAL AND METHODS

- Microimplant (S K surgicals, Wagholi Pune) 1.5 X 8 mm
- Mini-implant screw driver
- Mouth mirror for tongue impression
- Alginate
- Cold cure monomer liquid and polymer powder (DPI RR)
- Orthokal (Kalabhai) dental stone.
- 0.019x0.025" stainless steel wire

III. PROCEDURE

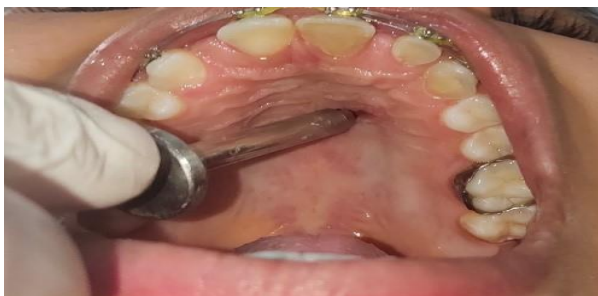

Figure 1: Placement of TAD with mini-implant screw driver.

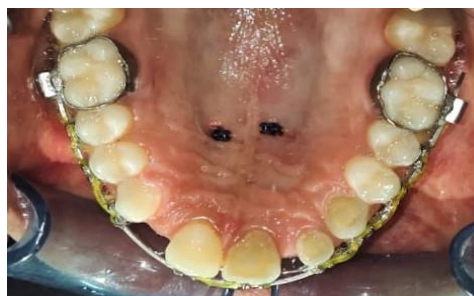

Figure 2: TADs placed in the palate.

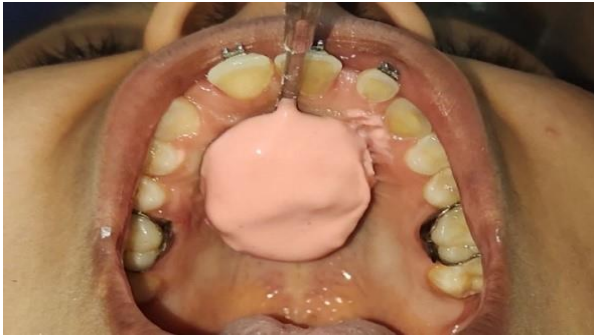


Figure 3: Mouth mirror as a holder for tongue impression

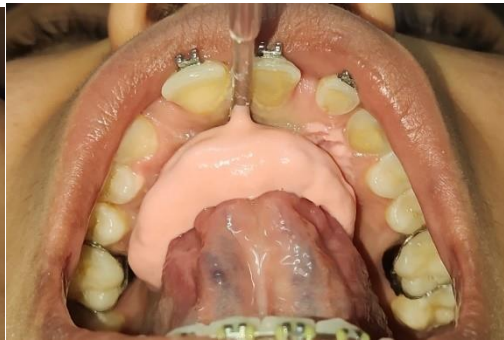

Figure 4: Recording the new, ideal Tongue position.



Figure 5: Working model with TADs.

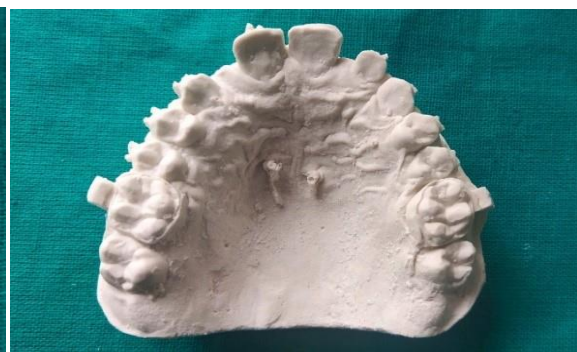

Figure 6: Replica of the anterior part of tongue.



Figure 7: Butterfly shaped wire framework.

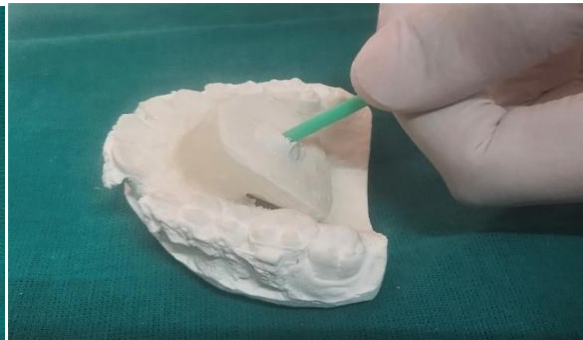
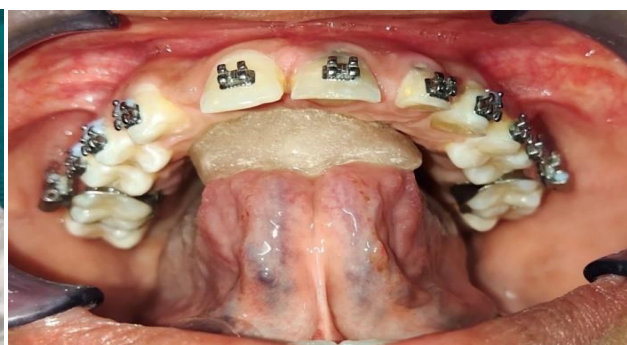
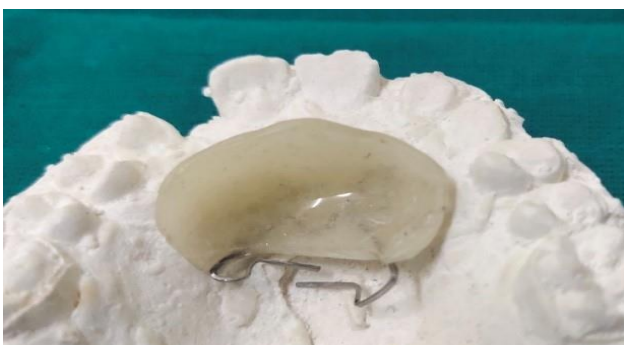Figure 8: Tongue replica adapted over the acrylic.



- Two Implants are placed in palate, in the 1st premolar region, about 3 mm away from the midline on both sides using an implant driver (**Fig. 1&2**). Favourable attached gingiva and thicker cortical bone in the anterior palate favours the stability of mini-screw placement. The optimal site for mini-screw placement is located 3-6 mm paramedian to the mid palatine suture and 6-9 mm distal to the incisive foramen, in the 1st premolar region⁴.
- Then, the impression of upper arch is recorded along with TADs using alginate impression material.
- An additional impression of anterior part of the dorsal surface of the tongue is to be recorded. For this, a small amount of alginate material is mixed and positioned over the mouth mirror, acting as an accessible holder for recording the same, which is placed just behind the incisive papilla (**Fig. 3**).
- The patient is then guided to position the tongue over the concerned area and the impression is taken (**Fig. 4**).
- The impression is then poured with dental stone and a replica of upper arch and anterior part of tongue is achieved. (**Fig. 5&6**)
- A 0.019x 0.025” SS wire is used to make a Butterfly wing shaped wire framework with a centred U bend to secure the appliance design over the anterior part of the palate behind the incisive papilla on the working model with implant replica as the guide. (**Fig.7**)
- Cold cure monomer and polymer is mixed, and this mix in dough stage is placed over the U bend. Tongue replica model is adapted over the acrylic until the final stage is achieved. (**Fig. 8**)
- The final outcome is a cave like structure, which is finished and polished with pumice to achieve the gloss. (**Fig.9**)
- The try in is done clinically, and 0.019x0.025” SS wire framework is adjusted and ligated over the bracket head of TADs and secured with composite thereafter (**Fig. 10 &11**).
- Advantage:
 - Simple and easy to fabricate.
 - No laceration, trauma or any indentation of crib over the tongue.
 - Discards the absolute necessity of banding and thus, can be used in bonded molar attachments.
 - Not necessary to correct the alignment of molars as it avoids hindrance in molar axial corrections.
 - Can be used even after debonding the case.

IV. CONCLUSION

- Tongue cave is a customised appliance to habituate the patient's tongue in a new relaxed position.
- The discomfort of multiple bends of a crib is avoided and it is replaced by a smooth and easily adaptable surface with better acceptance by the patient.
- It can be used during and after the treatment with an excellent compliance in adults.

REFERENCES

- [1.]Tulley WJ. A critical appraisal of tongue thrusting. Am J Orthod.1969;55:640-50.
- [2.]Osiewicz S, Malgorzata J,Elzbieta P. Tongue function correction appliances. The current state of knowledge and therapeutic possibilities including a device of own design- review of the literature. Dent Med Probl. 2015;52(2):227-234.
- [3.]Patni V, Kolge NE. TADs supported tongue crib: A new minimalistic design. J Contemp Orthod.2018;2(2):42-46.
- [4.]Ludwig B, Glasl B, Bowman SJ, Wilmes B, Kinzinger GS, Lisson JA. Anatomical guidelines for miniscrew insertion: palatal sites. J Clin Orthod.2011;45(8):433-441.