

Atypical Case of Presumed Ocular Tuberculosis Presenting as Unilateral Occlusive Vasculitis

Dr. Elakhdari Meriem^{1*},
 Dr. Akannour Younes²,
 Dr. Bardi Chaimaa³,
 Dr. Mrad Khalil⁴,
 Dr. Hassina Salma⁵,
 Dr. Kamal Elmajdoubi⁶,
 Serghini Louai⁷,
 El Hassan Abdellah⁸,
 Berraho Amina⁹

Department of Ophthalmology B; Hospital of Specialties, Rabat, Morocco

*Corresponding Author

Abstract:- Tuberculosis affects the lungs in 80% of patients, while in the remaining 20% the disease may affect other organs, including the eye. Ocular tuberculosis can affect all ocular tissues, the diagnostic remains difficult (1). We present a case of a 22-year-old man, who presented with unilateral neuroretinitis with occlusive vasculitis, diagnosed as presumed ocular tuberculosis. The purpose of our case is to show an atypical clinical presentation of tuberculosis.

Keywords: *Mycobacterium Tuberculosis, Presumed Ocular Tuberculosis, Posterior Uveitis.*

I. INTRODUCTION

Tuberculosis (TB) is a multisystem infectious disease caused by *Mycobacterium Tuberculosis*, (2) it has a proclivity to cause caseating granulomatous inflammation, which primarily affects the lungs but can also impact various other organs in the body. (1)

Ocular tuberculosis is a specific presentation of mycobacterial infection generally caused by direct invasion of the tuberculosis bacilli or an immunogenic reaction secondary to an extraocular infection. (1)

The diagnosis of ocular tuberculosis remains challenging, and it is based on a combination of arguments. (3)

➤ Case Report:

Case of a 22-year-old man, with tuberculosis contagion history (1 year before brother treated for tuberculosis), who consulted for decrease in visual acuity on his left eye which was insidious in onset, gradually progressive in nature, without associated signs.

Ophthalmological examination revealed a limited visual acuity to detect hand motions, the intraocular pressure

and the anterior segment were normal, slit-lamp exam showed no signs of anterior segment inflammation.

Fundus examination after dilation revealed papilledema stage 2, with perimacular exudates, multiple retinal flames and spots hemorrhages, with tortuous vessels. (Figure 1)

Fluorescein angiography of the eye was done, showing a peripapillary diffusion of the dye confirming the papillary oedema and, in the vessels, confirming the vasculitis, with the presence of hemorrhages realizing a mask effect, and zones of ischemia. (Figure 2)

OCT showed an important cystoid macular oedema with retinal serous detachment. (Figure 3)

We described a case of unilateral neuroretinitis with occlusive retinal vasculitis.

The patient underwent an extensive evaluation, including *Treponema pallidum* hemagglutination and Venereal Disease Research Laboratory test, cyclic citrulline peptide, herpes simplex virus and cytomegalovirus serology, HIV, toxoplasmosis antibody, rheumatoid factor, antinuclear antibody, Quantiferon Gold, Mantoux test, angiotensin converting enzyme level, Lyme antibody, and chest x-ray. There were all negative, except for the Quantiferon Gold, and the Mantoux test which was found strongly positive; 20 mm induration. The lumbar puncture was normal.

A diagnosis of posterior uveitis secondary to presumed ocular tuberculosis in the left eye was made.

A 4 drug-therapy was started including Rifampin, Isoniazid, Pyrazinamide, and Ethambutol.

He received it for 55 days and then Rifampin and Isoniazid during the continuation phase of treatment.

The Methylprednisolone (10mg/Kg/d) commenced 48 hours after the initiation of tuberculosis treatment and continued for three days. This was then followed by a daily intake of 20 mg of prednisone, with a gradual decrease in dosage.

II. DISCUSSION

Ocular tuberculosis is a rare extrapulmonary manifestation of *Mycobacterium tuberculosis* infection. Ocular involvement occurs from hematogenous dissemination from the lungs to the uveal tract. (4)

Definitive diagnosis of TB uveitis is only made when *Mycobacterium tuberculosis*, or its DNA, is isolated from ocular fluids. In most cases, ophthalmologists are unable to make a definitive diagnosis, a clinical diagnosis is typically not possible due to the fact that the disease presentation is often indistinguishable from other etiologies of uveitis, and it is a great imitator of ocular pathologies (4), also a definitive diagnosis requires isolation of bacilli from the ocular tissue which is difficult to obtain. (3)

If one of these features is present; confirmed TB exposure (positive Quantiferon Gold, and Mantoux test), evidence of a tubercular lesion on a chest x-ray or CT scan,

the diagnosis of presumed ocular tuberculosis should be made, and treatment should be offered. (4)

We presented an atypical case of unilateral posterior uveitis in the form of neuroretinitis with occlusive retinal vasculitis, diagnosed as presumed ocular tuberculosis on the following criteria: history of tuberculosis contagion, the Quantiferon Gold; and the Mantoux test were positive.

Treatment with quadruple antitubercular regimen for at least 6 months shows good clinical outcomes. However, it is still unclear whether steroid use is beneficial or not. (5)

III. CONCLUSION

In summary tuberculosis is a relatively rare cause of ocular diseases (6), and it is often a challenging diagnosis with extremely diverse clinical manifestations and, most time, impractical bacilli isolation. (7)

Diagnosis and therapeutic management are urgent to preserve the anatomical and functional prognosis of the eye.

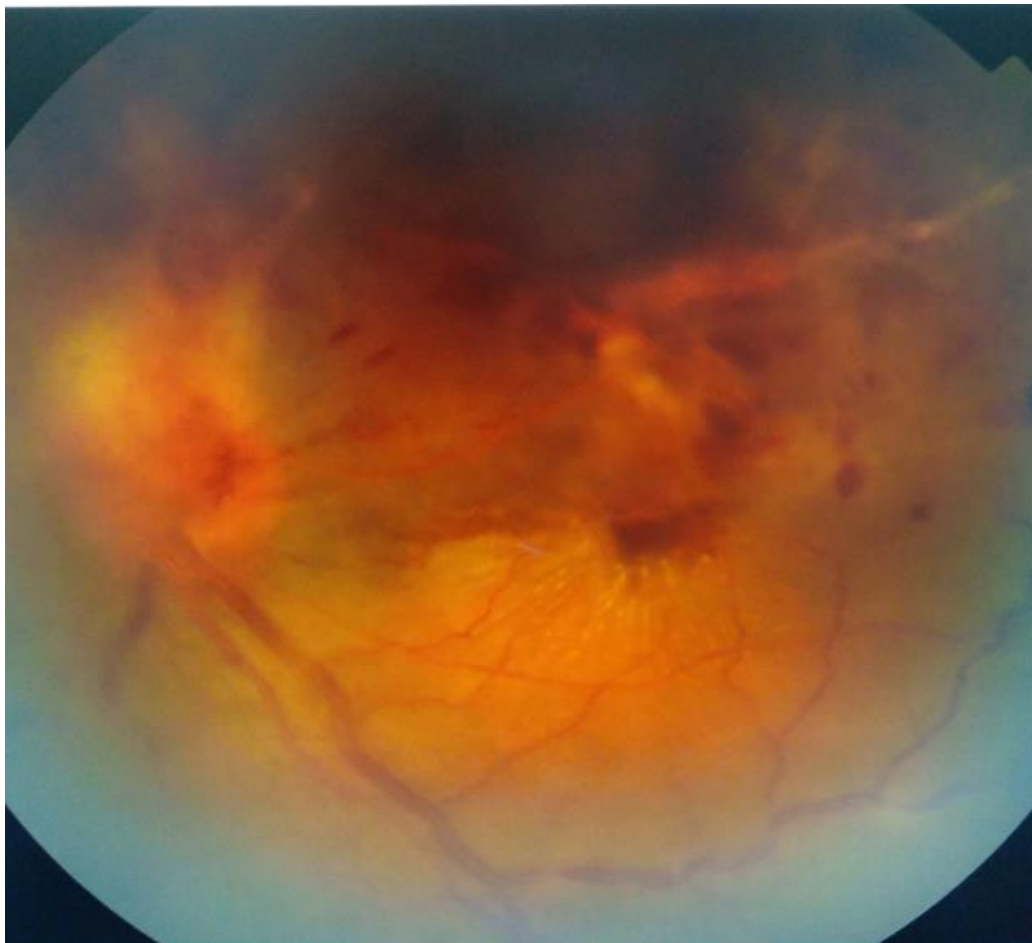

Fig 1 Fundus photographie of the left eye showing a papilledema stage 2, with perimacular exudates, retinal flames and spots hemorrhages, with cotton wool spots tortuous vessels and vasculitis.

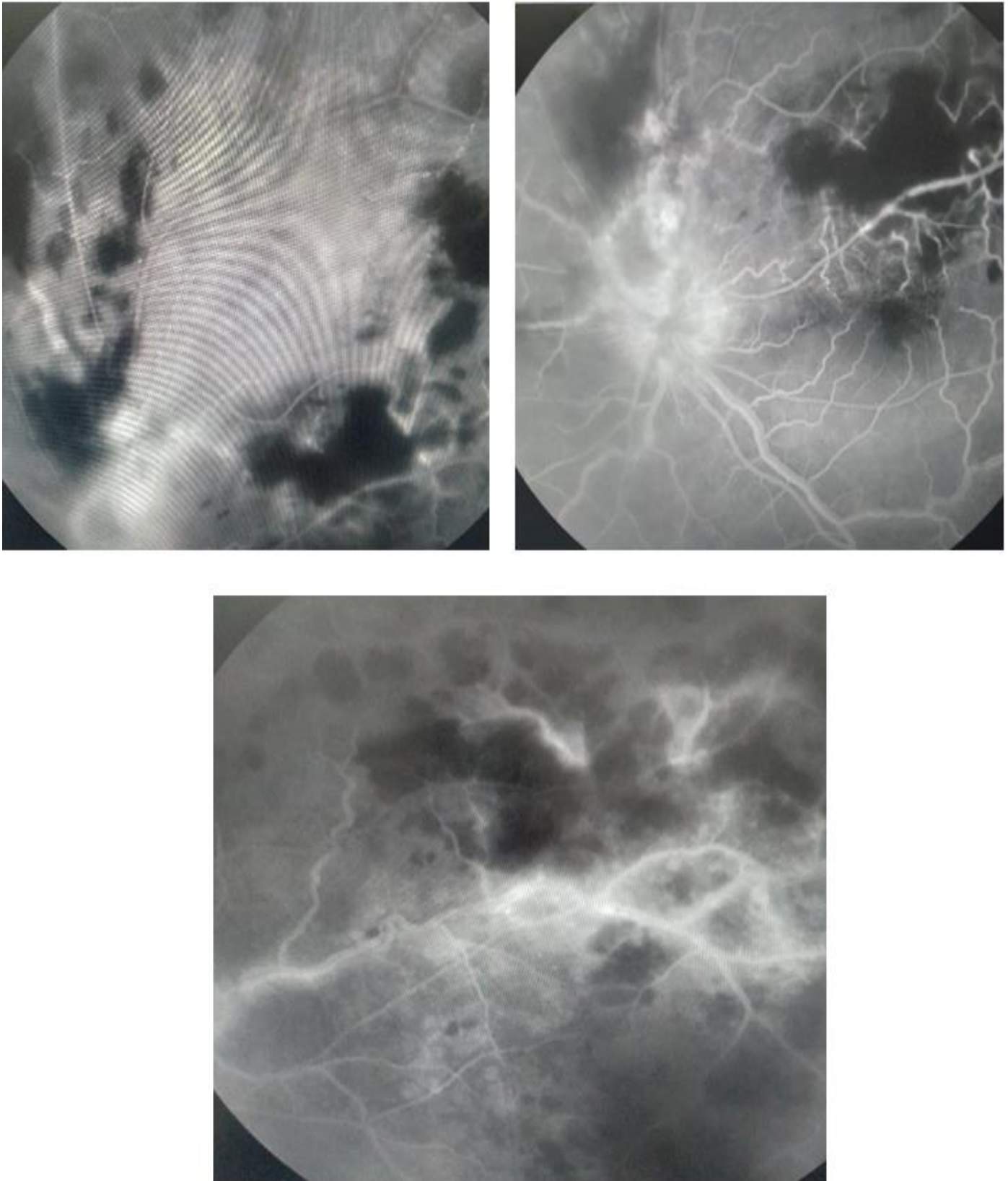


Fig 2 Fluorescein angiography of the left eye showing a peripapillary diffusion of the dye and in the vessels, with the presence of hemorrhages realizing a mask effect, and zones of peripheral ischemia

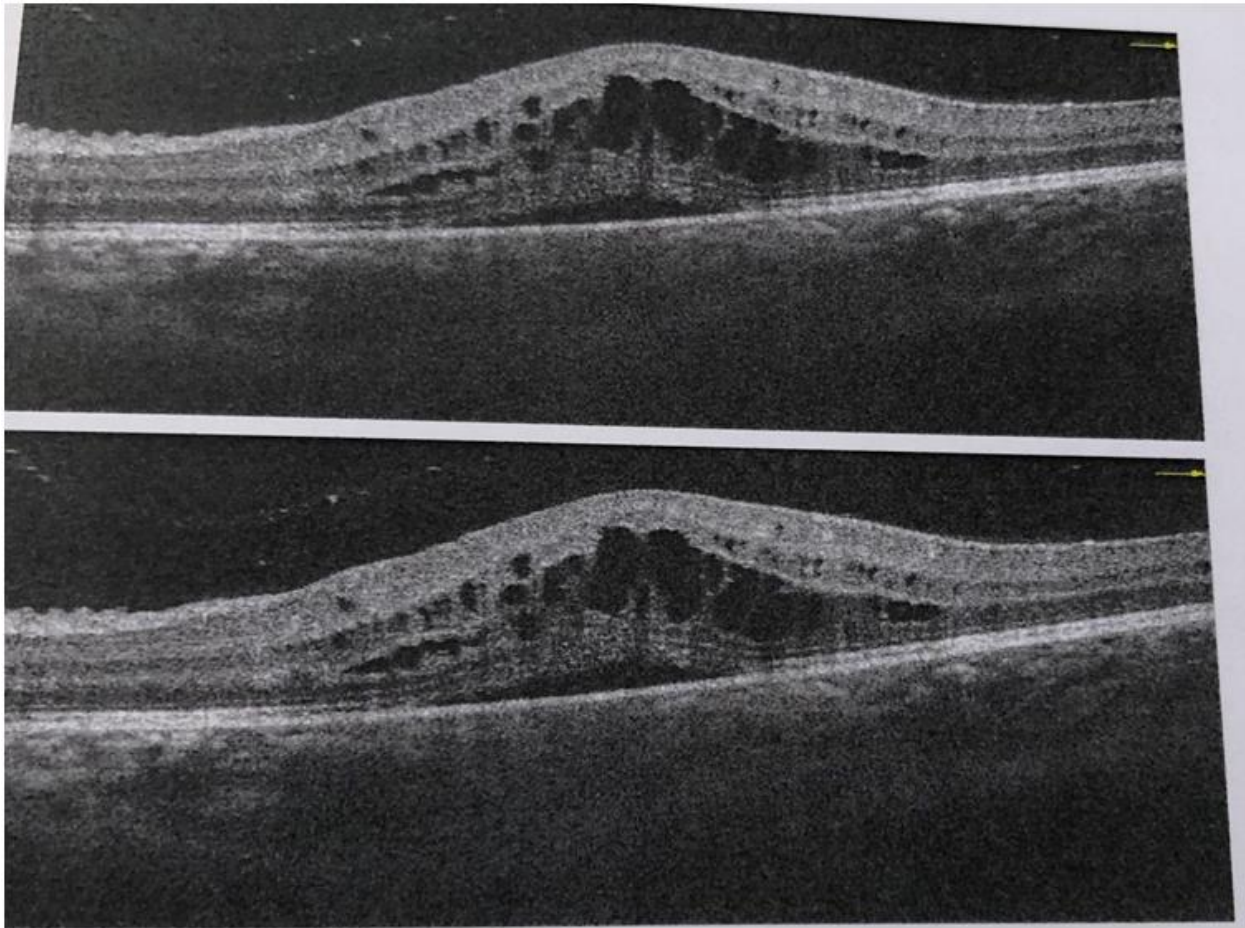


Fig 3 Macular OCT of the left eye showing cystoid macular oedema with retinal serous detachment.

❖ **Abbreviations:**

- HIV: human immunodeficiency virus
- TB: tuberculosis

REFERENCES

- [1]. Shakarchi. F I, Ocular tuberculosis: current perspectives, Published online 2015 Nov 26. doi: 10.2147/OPHTH.S65254, Clin Ophthalmol. 2015; 9: 2223–2227.
- [2]. Nandu N, Bavanasi A, Wajahat R (May 01, 2020) Ocular Tuberculosis Without a Lung Primary. Cureus 12(5): e7920. doi:10.7759/cureus.7920
- [3]. Burkes W, Freedman K, Dominguez L. Panuveitis: a case of suspected ocular tuberculosis. The Southwest Respiratory and Critical Care Chronicles 2018;6(26):1–5
- [4]. Neuhaus J A; Sallam .A, Ocular Tuberculosis. National library of medicine. July 25, 2022.
- [5]. Shirley, K., Dowlut, S., Silvestri, J. et al. Presumed ocular tuberculosis in the United Kingdom: a British Ophthalmological Surveillance Unit (BOSU) study. Eye 34, 1835–1841 (2020). <https://doi.org/10.1038/s41433-019-0748-9>.
- [6]. Clever. V G, presumed ocular tuberculosis, Case Reports Ann Ophthalmol, .1980 Apr;12(4):424-6
- [7]. Melo. I M, Caroline Ferreira Gomes. R, Amaral Yung. A, Unique case of presumed ocular tuberculosis presenting as bilateral pseudoretinitis pigmentosa. American Journal of Ophthalmology Case Reports. Volume 26, June 2022, 101412