

# Role of MRI in Diagnosing Placenta Accreta Spectrum Disorders: Evaluating the Sensitivity & Specificity of MRI in Detecting Placenta Accreta, Increta & Percreta Compared to Ultrasound

Dr. Nabin Kumar Yadav<sup>1</sup>; Farjana Afrin<sup>2</sup>; Mohammad Ahamadullah<sup>3</sup>; Bibha Yadav<sup>4</sup>

<sup>1,2,3,4</sup> Department of Radiology, Obstetrics & Gynaecology, Surgery, Medicine

Publication Date: 2025/05/27

**Abstract:** The Placenta Accreta Spectrum (PAS) disorder spectrum, the Placenta Accreta is the most severe—along with increta and percreta—carry high risks in pregnancy, which include excessive bleeding and severe maternal morbidity or mortality. A matrix scan (MRI) ultrasound serves best in prenatal imaging. Accurate diagnosis allows for the best preparations to made and life saving interventions to be performed on time. This paper researches the use of MRI and Ultrasound in combination with imaging for the diagnosis for placenta accreta spectrum (PAS), evaluating their comparative effectiveness in terms of sensitivity, specificity, and diagnostic accuracy.

**Keywords:** MRI, Placenta, PAS, Ultrasound, Diagnostic, Accuracy.

**How to Cite:** Dr. Nabin Kumar Yadav; Farjana Afrin; Mohammad Ahamadullah; Bibha Yadav. (2025). Role of MRI in Diagnosing Placenta Accreta Spectrum Disorders: Evaluating the Sensitivity & Specificity of MRI in Detecting Placenta Accreta, Increta & Percreta Compared to Ultrasound. *International Journal of Innovative Science and Research Technology*, 10 (4), 4255-4257. <https://doi.org/10.38124/ijisrt/25apr2332>

## I. INTRODUCTION

The three main subtypes are accreta, increta, and percreta, each ranging in severity and correlating with increased risk of complications and even death due to the attachment of the placenta implacable to lesions within the walls of the uterus. As a result, timely precision ensures adequate cesarean and complete hysterectomy planning follows. MRI is the primary technique because it uses ultrasound imaging, but is often supplemented by ultrasound for more complicated issues or ambiguous ultrasound results. Decision making around imaging for PAS tends to be far superior with interventional guidance.

### ➤ Placenta Accreta Spectrum Disorders

- Placenta Accreta: The placenta develops attached to the myometrium without the characteristic of invasion.
- Placenta Increta: The placenta invades into the myometrium.
- Placenta Percreta: The placenta goes through the myometrium and may protrude through adjacent organs such as the bladder.
- These disorders could cause significant consequences like hemorrhage which requires prompt diagnosis, and treatment.

### ➤ Diagnostic Imaging Modalities

#### • Ultrasound

Ultrasound remains the primary imaging procedure of choice when assessing PAS and has distinct features which aid diagnosis:

#### • Placental lacuna:

These are areas which are void of placental echogenic.

#### • Myometrial thinning or interruption:

The echogenic outline depicting the uterus is absent.

#### • Excessive blood supply:

As shown with color Doppler imaging.

Ultrasounds are easy to operate and it doesn't harm to the patient, but, as with many other technologies, the skill of the operator may influence the results, and some cases can be difficult to interpret.

#### • Magnetic Resonance Imaging (MRI)

Ultrasound can sometimes be inconclusive. In this scenario, detailed anatomy imaging is sought through MRI. Ultrasound images the soft tissues of the body and can clearly look at the lower region of abdomen containing the

uterus and its adjacent structures. Findings which are associated with PAS using MRI include but are not limited to the following:

- *Intraplacental T2 dark bands:*  
Which indicate muscle layer encroachment.
- *Bladder wall interruption or tenting:*  
Indicating possible placental invasion into adjacent structures.
- *Heterogeneous placental signal intensity:*  
Reflecting abnormal placental tissue.

## II. PATIENT DIAGNOSIS SUMMARY

In this study 100 Pregnant Patients with suspected placenta Accreta Spectrum (PAS) disorders were evaluated using both Ultrasound & MRI (Magnetic resonance Imaging)

Among these patients 70 were confirmed to have PAS Disorders (Placenta Accreta, Increta, Percreta) based on intraoperative findings and histopathological confirmation.

The USG Performance correctly identified 63 out of 70 Placenta Accreta Spectrum Case. And it correctly ruled out PAS in 25 patient out of 30 patients without PAS.

The MRI Performance correctly identified 62 out of 70 PAS cases. It correctly ruled out PAS in 26 patients out of 30 patients without PAS.

Table 1 Diagnostic Performance Summary Table

| Parameter                 | Ultrasound | MRI   |
|---------------------------|------------|-------|
| Total No. of Patient      | 100        | 100   |
| Confirmed Cases           | 70         | 70    |
| True Positive             | 63         | 63    |
| False Negative            | 7          | 8     |
| True Negative             | 25         | 26    |
| False Positive            | 5          | 4     |
| Sensitivity               | 90%        | 89%   |
| Specificity               | 83%        | 87%   |
| Positive Predictive Value | 92.6%      | 93.9% |
| Negative Predictive Value | 78.1%      | 76.5% |

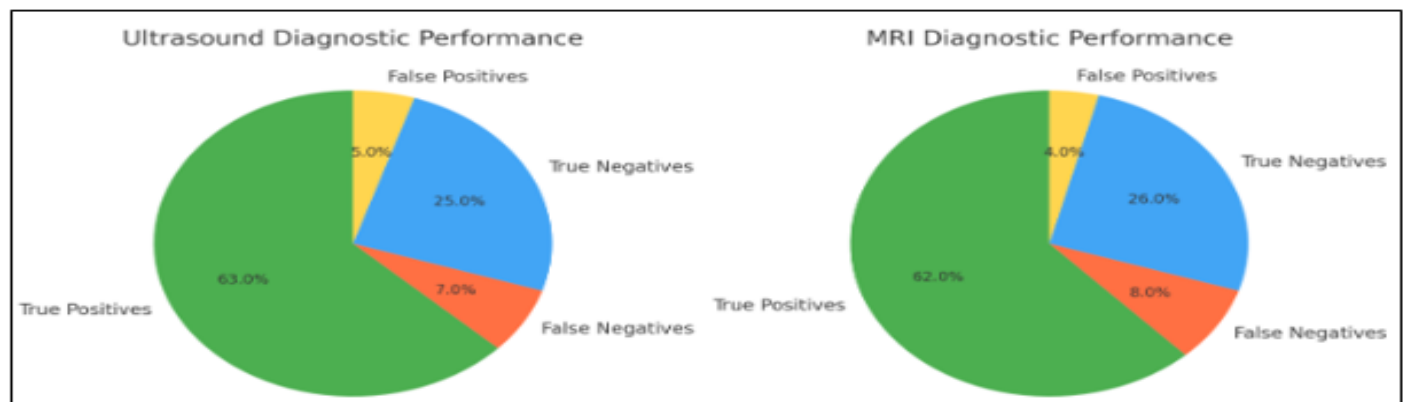


Fig 1 Ultrasound Diagnostic Performance & MRI Diagnostic Performance

### ➤ Sensitivity and Specificity

- *Sensitivity:*  
The ability of a test or Findings people who actually have the disease
- *Specificity:*  
The ability of a test or findings to correctly identify those who do not have the disease.

slightly higher sensitivity, MRI demonstrated superior specificity. Both modalities offered high accuracy; however, accuracy with specificity was slightly higher for MRI than ultrasound.

### ➤ Structured Reporting in MRI

The outline of a case study conducted by Raj et al. (2024) indicates that the incorporation of structured reporting in MRI is linked with improvement in diagnostic accuracy. Structured MRI Reporting Is Associated With Enhanced Sensitivity and Specificity for Diagnosing Percreta Placenta.

## III. COMPARATIVE ANALYSIS: MRI VS. ULTRASOUND

Both MRI & USG showed high Sensitivity & Specificity in diagnosing PAS disorders. Ultrasound had

➤ *Clinical Decision-Making*

Both ultrasound and MRI play crucial roles in the diagnosis of PAS disorders. Ultrasound serves as an effective first-line screening tool, while MRI provides detailed anatomical insights, particularly in complex cases. The integration of both modalities, guided by clinical indications and available resources, ensures optimal management of PAS.

#### IV. DISCUSSION

Both ultrasound and MRI serve crucial in regard to routine peripheral prenatally assigned diagnosis of PAS. While ultrasound works efficiently during screening periods of use, MRI is supplied for use in closed and open months of detail for the purpose of planning surgery. Preparedness of both imaging modalities combined with structured reporting is most beneficial for accurate and timely diagnosis & protocols can optimize diagnostic accuracy and improve patient outcomes.

#### V. CONCLUSION

Precision in the ultrasound evaluation of the placenta is critical for proper care and better outcomes in the mother. Ultrasound is the primary imaging tool; however, MRI provides important additional details in more challenging cases. The use of both imaging modalities, along with documented templates, greatly improves the diagnostic performance and assists in clinical actions.

#### ACKNOWLEDGEMENTS

We extend our sincere gratitude to the dedicated staff of the Department of Radiology, Obstetrics and Gynaecology & Surgery Departments for their unwavering support and expertise in facilitating this research. Our heartfelt thanks to the families and patients who participated, offering invaluable cooperation and trust. Your contributions have been instrumental in the success of this study.

#### REFERENCES

- [1]. D'Antonio, F., et al. (2022). Performance comparison of ultrasonography and magnetic resonance imaging in their diagnostic accuracy of placenta accreta spectrum disorders: a systematic review and meta-analysis. *Insights into Imaging*. [Link](#)
- [2]. Raj, G., & Raj, R. (2024). EP16.29: Comparative analysis of ultrasound and MRI in diagnosis of placenta accreta spectrum. *Ultrasound in Obstetrics & Gynecology*, 64(S1), 257. [Link](#)
- [3]. American Journal of Roentgenology. (2016). MRI of Placenta Accreta, Placenta Increta, and Placenta Percreta: Pearls and Pitfalls. [Link](#)
- [4]. D'Antonio, F., et al. (2013). Prenatal Diagnosis of Placenta Accreta: Sonography or Magnetic Resonance Imaging? *PMC*. [Link](#)