

Efficacy of Progressive Resistance Training Protocol in Avascular Necrosis Patient: A Case Study

Dr. Pratiksha Akhade¹; Dr. Neeraj Kumar²

¹Master of Musculoskeletal Physiotherapy, ²Vice Principal and HOD

^{1,2}Department of Orthopaedic Physiotherapy, Dr. APJ Abdul Kalam College of Physiotherapy, Pravara Institute of Medical Sciences, Loni Bk Ahmednagar, Maharashtra, India

Publication Date: 2025/06/12

Abstract: The purpose of this case study was to investigate the effect of progressive resistance training protocol on pain, restricted movement, strength, and functional ability of patient with avascular necrosis (AVN). A single case study was done on patient with AVN, baseline data was collected pre and post the treatment and outcome measures pain, range of motion (ROM) of hip and muscle strength were assessed using the Numerical Pain Rating Scale (NPRS), Goniometer and Manual Muscle Testing (MMT) respectively. The treatment program was a total of 4 weeks with 3 sessions per week. Results showed a significant decrease in pain intensity and an increase in range of motion and strength. This study concluded that a progressive resistance exercise training program showed substantial improvement in hip musculature strength and helped in regaining pain-free range of motion in a patient with AVN.

Keywords: Avascular Necrosis, Progressive Resistance Training, Physiotherapy, Rehabilitation Protocol, Conventional Exercise.

How to Cite: Dr. Pratiksha Akhade; Dr. Neeraj Kumar. (2025). Efficacy of Progressive Resistance Training Protocol in Avascular Necrosis Patient: A Case Study. *International Journal of Innovative Science and Research Technology*, 10(6), 368-374. <https://doi.org/10.38124/ijisrt/25jun220>.

I. INTRODUCTION

Avascular Necrosis of the femoral head is a severe medical condition with a multifaceted pathophysiology that eventually leads to hip joint degeneration, also known as Osteonecrosis of the femoral head or aseptic necrosis of the femoral head [1]. It is generally characterized by the cellular death of bone cells, including bone marrow, osteoblast cells, and osteoclast cells. This causes bone collapse as well impacting the cartilage, flattens the surface of the head of femur, ultimately resulting in secondary osteoarthritis [2].

In clinical settings, avascular necrosis is a disease that is frequently seen in the femoral head [3]. A disturbance in blood flow causes the degenerative disorder known as non-traumatic avascular necrosis of the femoral head. For people of any age, this chronic, complex, and impairing illness can result in substantial morbidity. The cause and prevalence of non-traumatic avascular necrosis of the femoral head are unknown, regardless of the presence of distinct clinical signs [3].

On an annual basis, 20,000-30,000 new cases of ONFH are reported. The majority of patients are men aged 35 to 45, whose quality of life and livelihood are highly being compromised. As a result, it is of great interest to health-care providers. Its treatment demands to prevent further

degeneration of the joint. Patients who do not receive treatment will have significant pain and limited movement as the condition progresses [1].

AVN may have an idiopathic, nontraumatic, or posttraumatic etiology. A limp and limited mobility at the afflicted joint were its defining characteristics, along with pain and discomfort that is primarily felt in front of the joint. There are several different areas that make up pathophysiology. A compromised terminal artery supply to the bone and a complicated process of bone resorption and creation lead to a regular series of cell death. The femoral head's surrounding joint cartilage is lost during the necrosis phase, hastening the deterioration process. The femoral head is gradually deformed by the joint, shortening the lower leg [4]. Based on radiographic abnormalities, bone scan results, and clinical symptoms, Ficat and Arlet developed a grading system for avascular necrosis. Other than decreased activation on bone scans, radiographs in stage How to cite this article 0, a preclinical stage, show no abnormalities. Clinical symptoms and elevated bone scan uptake are characteristics of stage I. Stage II radiographs display abnormalities that are either cystic or sclerotic. While femoral head flattening and hip joint arthritic abnormalities are seen in stage IV, the radiographic crescent sign with joint space is intact in stage III [3].

AVN's major therapeutic approaches are divided into operative (surgical) and non-operative (conservative) treatments. Surgical procedures like Core decompression, osteotomy, bone transplantation, and joint replacement are included. Medication, weight-bearing restriction, and physical therapy are some examples of conservative treatments. The primary aims of nonoperative therapies are to relieve symptoms, prevent disease progression, and improve functioning. Patients in the early (Arco stage: 0-I) or middle phases (Arco stage: II-III), weight-bearing with crutches or other walking aids are advised to restore function and ease painful symptoms [1].

Progressive resistance training (PRT) is frequently used to improve muscular strength. During the exercise, participants use their muscles against some form of resistance that gradually increases as strength grows. Exercise machines, free weights, and elastic bands are some of the most common PRT equipment [5]. Additionally, studies in hip OA have indicated that progressive resistance training (PRT) appears to be a beneficial exercise strategy with improvement in pain, physical function, and quality of life. The often-seen muscular atrophy and weakness in patients with hip OA provide a basis for PRT, which is widely regarded as the most effective intervention for increasing muscle mass and strength, thus relieving pain and improving function. To our knowledge, there is a lack of research trials using PRT in femoral avascular necrosis [6,7].

II. CASE PRESENTATION

A. Patient Details

A 44-year-old farmer with right-hand dominance presented to the hospital with complaints of lower back and groin pain, as well as stiffness in his left hip joint that had persisted for a year. The patient has no history of swelling, fever, or clinical signs that could compromise their health. There is no history of alcohol consumption or blood transfusions. No particularly notable family history or prior

surgical history is present. The patient had taken steroids for COVID-19 two years before the presentation of the illness. For a few months, the patient was apparently well when he began to feel pain in his left hip. The patient described a dull pain that started gradually, progressed over time, and aggravated when moving his left limb. The pain was minimized by rest and medication. Following the evaluation, the patient's pain score on the numeric pain rating scale (NPRS) was 8/10. Walking, squatting, and other everyday tasks were challenging due to the hip's limited range of motion. The patient visited a local physician and was prescribed NSAIDs to treat his pain, but when no improvement was observed, he decided to go to the orthopaedics outpatient department. On November 2, 2024, the patient was referred for physiotherapy after orthopaedic surgeons recommended X-ray and MRI tests and determined that the patient had avascular necrosis of the left femoral head.

B. Clinical Findings

The patient's written consent was obtained. He received a thorough explanation of every step involved in the examination and subsequent management. The patient's vital signs were normal upon general examination: Afebrile with a BMI of 29.07 kg/m², a pulse rate of 86 beats per minute, a respiratory rate of 20 breaths per minute, and a blood pressure of 127/80 mm Hg. Upon examination, the underlying skin seemed normal. Based on the numerical pain rating scale, the patient's pain score was 8 out of 10. Upon examination, the local temperature did not rise; however, there was grade 2 tenderness near the anterior joint line. The distal extremity's circulation was completely intact. Reflexes and sensory examination were normal on both sides during the neurological evaluation. Prior to treatment, the left (affected side) hip's range of motion was significantly limited and uncomfortable in every range (Table 1). Pre-treatment muscle weakness was observed in the left lower leg (Table 2). Upon gait analysis, a modified gait pattern was observed, exhibiting a mild waddling gait and a reduction in the stance phase.

Table 1: ROM of Hip Joint Pre-Treatment Assessment in Degree

Hip Joint	Left (affected side)	
	Active	Passive
Flexion	0-70	0-80
Extension	0-15	0-20
Abduction	0-20	0-27
Adduction	0-20	0-25
Medial Rotation	0-20	0-25
Lateral Rotation	0-25	0-30

ROM- Range of Motion

Table 2: Muscle Manual Testing pre-Assessment

Muscles	Left (affected side)
Flexors	3/5
Extensors	3/5
Abductors	3/5
Adductors	3/5
Medial rotators	3/5
Lateral rotators	3/5

III. DIAGNOSTIC ASSESSMENT

The X-ray findings reveal the pelvis with both hips in anteroposterior (AP) view (Fig.1) showed sclerotic changes with small lytic lesions in left femoral head and irregularities

in the shape of the head of femur with crescent sign maintained. Magnetic resonance imaging of was conducted on October 07, 2024, which revealed stage 2 avascular necrosis of left femoral head according to the Ficat and Arlet classification.

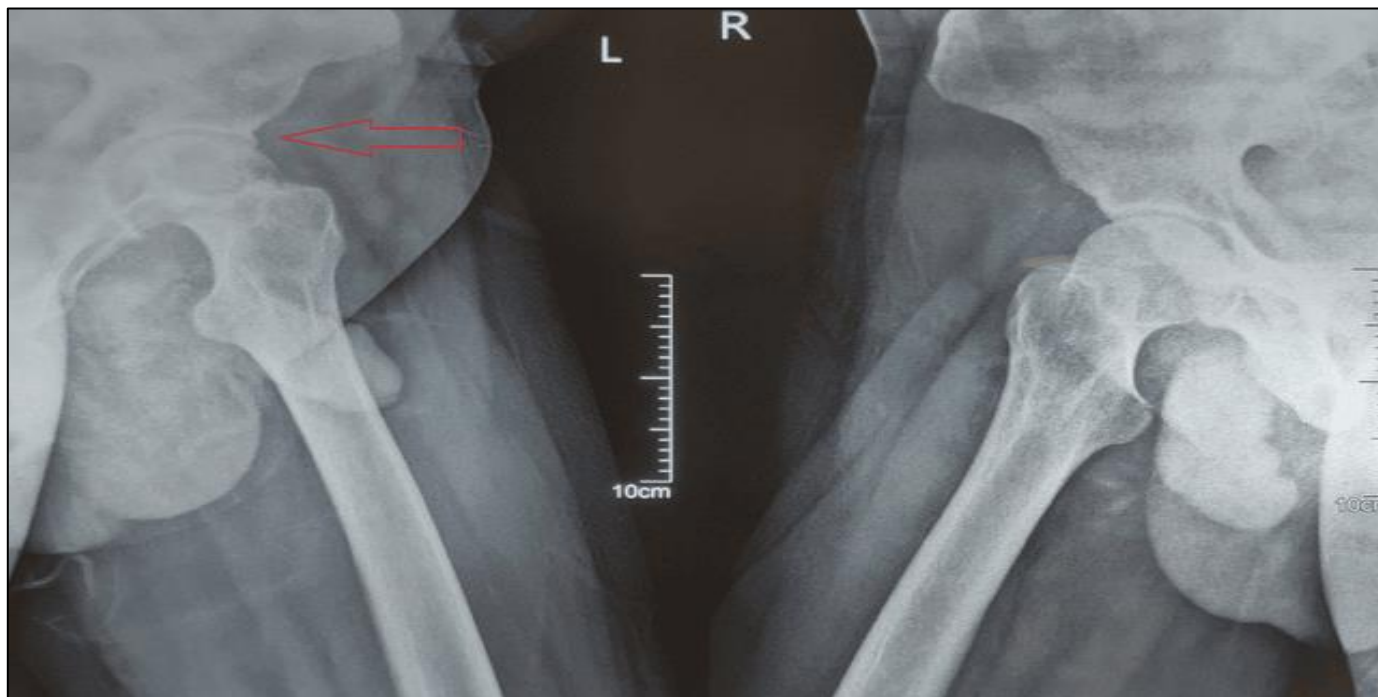


Fig 1: X-Ray of Pelvis (Anteroposterior View)

IV. PHYSIOTHERAPY INTERVENTION

The protocol given in Table 3 was designed by the author and validated by professional physiotherapists who

had more than 10 years of experience in academics and clinical. Their suggestions were considered, and accordingly, modifications were made before implementation.

Table 3: Physiotherapy Intervention

Days	Intensity	Type of Exercise	Repetition/Sets
0-2d	NA	-Static Quadriceps -Static Hamstrings -Static Gluteal -Static Abdominals -Active Range of Motion for lower extremity in supine lying	10 reps x 3 sets with 5 sec hold
2-5d	NA	-Pelvic Bridging (initiation) -Dynamic Quadriceps -Active Range of Motion for lower extremity in standing with support	10 reps x 3 sets with 5 sec hold
5-7d	NA	-Pelvic Bridging -Frog bridging(initiation) -Dynamic Quadriceps -Active Range of Motion for lower extremity with isometric hold -Squats	10 reps x 3 sets with 5 sec hold
Week 2	50% of 10 RM	-Pelvic Bridging -Frog bridging -Dynamic Quadriceps -Squats -Heel raise	10 reps x 3 sets with 5 sec hold
Week 3	75% of 10 RM	-Pelvic Bridging -Frog bridging -Dynamic Quadriceps -Squats	10 reps x 3 sets with 5 sec hold

		-Heel raise	
Week 4	100% of RM	-Pelvic Bridging -Frog bridging -Dynamic Quadriceps -Squats -Heel raise	10 reps x 3 sets with 5 sec hold

RM- Repetition Maximum, NA- Not Applicable

Protocol is a total of 4 weeks, 3 sessions per week. All exercises were performed within pain-free range, without use of trick or forced movements. According to the protocol some of the exercises like Static Quadriceps (Fig.2), Static Hamstring (Fig.3), Dynamic Quadriceps with weight-cuff (Fig.4), Pelvic Bridging with dumbbell (Fig.5), Heel raises with dumbbell (Fig.6) are shown in the images which were performed by the patient.



Fig 2: Static Quadriceps



Fig 4: Dynamic Quadriceps with Weight Cuff



Fig 5: Pelvic Bridging with Weight

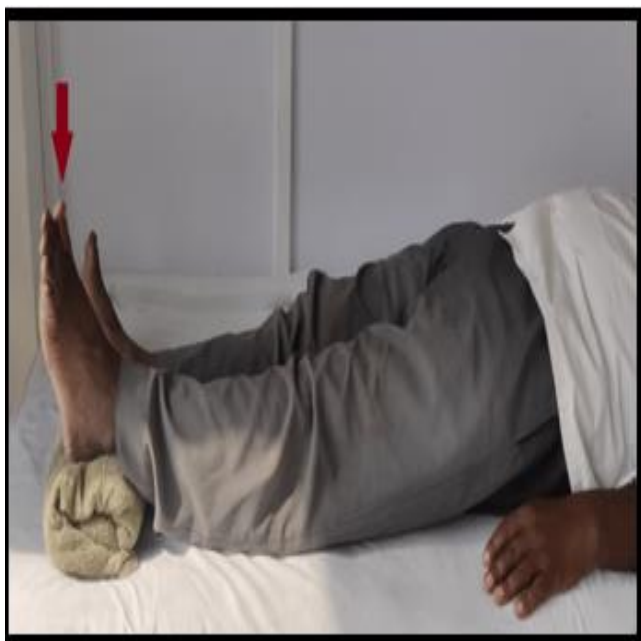

Fig 3: Static Hamstrings



Fig 6: Heel Raises with Weights

V. RESULTS

The participant tolerated the 4-week intervention well and completed the Progressive Resistance Training protocol without any adverse effects. Table 4 shows the pre and post

intervention changes in pain according to NPRS. According to Table 4 and Table 5 significant improvement was seen post intervention on patients Hip ROM and muscle strength respectively.

Table 4: Post-Treatment Assessment of Hip ROM

Hip Joint	Left (affected side)	
	Active	Passive
Flexion	0-100	0-110
Extension	0-25	0-30
Abduction	0-30	0-35
Adduction	0-25	0-30
Medial Rotation	0-25	0-30
Lateral Rotation	0-30	0-35

ROM- Range of Motion

Table 5: Muscle Manual Testing post-assessment

Muscles	Left (Affected Side)
Flexors	4/5
Extensors	4/5
Abductors	4/5
Adductors	4/5
Medial rotators	4/5
Lateral rotators	4/5

VI. DISCUSSION

A breakdown in the subchondral blood supply causes avascular necrosis, a degenerative bone disease, which is defined by the loss of bone cellular components. Other names for this condition include ischemic bone necrosis, aseptic necrosis, and osteonecrosis. Long bone epiphyses at weight-bearing joints are usually affected. Because there aren't many anastomoses, the femur's head has a very limited blood supply, which results in wedge-shaped avascular necrosis (AVN). Consequently, the femoral head is the most frequently affected area. It usually develops in irreversible joint deterioration, which restricts mobility and causes discomfort, leading to severe disability [8-15].

The development of a well-planned and concurrent physiotherapy intervention program began with simple exercises and progressed to strengthening activities. The program progressed to progressive resistance exercises after starting with hip range-of-motion exercises [11].

The purpose of this case study was to assess whether Progressive Resistance Training exercise protocol could serve as a feasible method to improve pain, hip strength, and hip range of motion in early-stage avascular necrosis patient. For this purpose, we recruited a participant and trained him for 4 weeks (3 times per week). After the intervention, the participant showed substantial improvements in pain, hip strength, and hip range of motion. There were also no adverse events during the training. These results suggest that 10 of 12 Progressive Resistance Training exercise protocol is a safe and feasible approach to improve hip strength and function and may serve as a promising adjuvant to traditional rehabilitation.

In a study on femoral head osteonecrosis, Karim et al., found that an exercise regimen improved the rate of recovery for patients after avascular necrosis [16]. After four weeks of treatment, the range of motion in the affected joints improved, according to the current study. From 8/10 to 5/10, the numerical pain rating scale decreased. The patient saw a considerable improvement in muscle strength, symptom reduction, and functional mobility that he had previously been unable to maintain because of discomfort.

In order to restore strength, range of motion, and functional activities as soon as possible after surgery for avascular necrosis, discovered that physiotherapy interventions such quadriceps strengthening and bedside activity training were beneficial.

According to Mortensen L et al., supervised progressive resistance training is attainable for people with hip dysplasia because it may enhance patient outcomes and discomfort levels. This case report's goals are to highlight the value of physical therapy rehabilitation and offer patients with avascular necrosis a thorough treatment plan [8].

The efficacy of customized physical treatment, which comprised core decompression and PRP infiltration, for surgical avascular necrosis was evaluated in a 2023 study [18]. The patient complained of pain, restricted range of motion (ROM), muscle weakness, and trouble lifting weights when they were referred to adaptive physical therapy. Restoring full range of motion, progressively increasing weight bearing, and preserving muscle strength in the appropriate muscles were the objectives of the rehabilitation process. According to this study, patients with postoperative avascular necrosis benefited from early strength, range of motion, and functional activities when a modified physical

therapy approach was employed. To limit the progression of the disease, the study was carried out in its early phases.

In conclusion, progressive resistance training physiotherapy rehabilitation protocol had significantly reduced pain, increased range of motion, and improved strength which helps in early rehabilitation. Setting clear objectives for the four-week program included maintaining the strength of the respective muscles, gradually increasing strength and weight bearing, and regaining pain-free range of motion. Additionally, this program helped raise awareness of the value of exercise treatment both before and after surgery. Exercise therapy sessions can help delay or lessen the need for hip replacement surgery.

CONFLICT OF INTEREST

No potential conflict of interest relevant to this article was reported.

All authors declare the following: No financial support was received from any organization for the submitted work. No financial relationships at present or within the previous three years with any organizations that might have an interest in the submitted work. No other relationships or activities that could appear to have influenced the submitted work.

ACKNOWLEDGMENTS

Data are available on reasonable request. The data are stored as de-identified participant data which are available on request to pratikshaakhade@gmail.com

REFERENCES

- [1]. Konstantonis A. Physical therapy intervention in early-stage femoral head osteonecrosis. *Journal of Research and Practice on the Musculoskeletal System* [Internet]. 2021 Feb 26;05(01):20–4. Available from: <https://doi.org/10.22540/jrpms-05-020>
- [2]. Guerado E, Caso E. The physiopathology of avascular necrosis of the femoral head: an update. *Injury* [Internet]. 2016 Dec 1;47:S16–26. Available from: [https://doi.org/10.1016/s0020-1383\(16\)30835-x](https://doi.org/10.1016/s0020-1383(16)30835-x)
- [3]. Mungal SM, Dhage P, Deshmukh NS. Effect of isolated hip musculature strengthening program in avascular necrosis: a case report. *Cureus* [Internet]. 2022 Oct 16; Available from: <https://doi.org/10.7759/cureus.30360>
- [4]. Saklecha AV, Wadhokar OC, Patil DS, Naqvi WM. Effect of physiotherapy rehabilitation on stage 4 Avascular necrosis of femur following pyogenic arthritis: a case report. *Pan African Medical Journal* [Internet]. 2022 Jan 1;41. Available from: <https://doi.org/10.11604/pamj.2022.41.17.32883>
- [5]. Liu CJ, Latham NK. Progressive resistance strength training for improving physical function in older adults. *Cochrane Library* [Internet]. 2009 Jul 3; Available from: <https://doi.org/10.1002/14651858.cd002759.pub2>
- [6]. Kjeldsen T, Dalgas U, Skou ST, Van Tulder M, Bibby BM, Mechlenburg I. Progressive resistance training compared to neuromuscular exercise in patients with hip osteoarthritis and the additive effect of exercise booster sessions: protocol for a multicentre cluster randomised controlled trial (The Hip Booster Trial). *BMJ Open* [Internet]. 2022 Sep 1;12(9):e061053. Available from: <https://doi.org/10.1136/bmjopen-2022-061053>
- [7]. Reimer LCU, Jakobsen SS, Mortensen L, Dalgas U, Jacobsen JS, Soballe K, et al. Efficacy of periacetabular osteotomy followed by progressive resistance training compared to progressive resistance training as non-surgical treatment in patients with hip dysplasia (PreserveHip) – a protocol for a randomised controlled trial. *BMJ Open* [Internet]. 2019 Dec 1;9(12):e032782. Available from: <https://doi.org/10.1136/bmjopen-2019-032782>
- [8]. Mortensen L, Schultz J, Elsner A, Jakobsen S, Søballe K, Jacobsen J, et al. Progressive resistance training in patients with hip dysplasia: A feasibility study. *Journal of Rehabilitation Medicine* [Internet]. 2018 Jan 1;50(8):751–8. Available from: <https://doi.org/10.2340/16501977-2371>
- [9]. Mikkelsen LR, Petersen AK, Mechlenburg I, Mikkelsen S, Søballe K, Bandholm T. Description of load progression and pain response during progressive resistance training early after total hip arthroplasty: secondary analyses from a randomized controlled trial. *Clinical Rehabilitation* [Internet]. 2016 Feb 6;31(1):11–22. Available from: <https://doi.org/10.1177/0269215516628305>
- [10]. Arbab D, König DP. A traumatic femoral head necrosis in adults. *Deutsches Ärzteblatt International* [Internet]. 2016 Jan 22; Available from: <https://doi.org/10.3238/arztebl.2016.0031>
- [11]. Choubisa CA, Hege AR, Phansopkar P. Physiotherapy rehabilitation post total hip replacement in the case of avascular necrosis of the femur: A case report. *Cureus*. 2023 Jan 6;15(1). Available from: <http://doi.org/10.7759/cureus.33465>
- [12]. Matthews AH, Davis DD, Fish MJ, et al. Avascular Necrosis. [Updated 2023 Aug 28]. In: StatPearls [Internet]. Treasure Island (FL): StatPearls Publishing; 2025 Jan. Available from: https://www.ncbi.nlm.nih.gov/books/NBK537007/?utm_medium=email&utm_source=transaction
- [13]. Ibinaieye PO, Musa AM, David SO, Okere PC. Avascular necrosis of both femoral heads following short-term high-dose steroid treatment for acute severe asthma-a rare presentation: case report and review of literature. *West African Journal of Radiology*. 2013 Jul 1;20(2):104–6. Available from: <https://doi.org/10.4103/1115-1474.121103>
- [14]. Shaharir SS, Chua SH, Mohd R, Mustafar R, Noh MM, Shahril NS, Said MS, Rajalingham S. Risk factors for symptomatic Avascular Necrosis (AVN) in a multi-ethnic Systemic Lupus Erythematosus (SLE) cohort. *PLoS One*. 2021 Mar 19;16(3):e0248845. Available from: <https://doi.org/10.1371/journal.pone.0248845>
- [15]. Pawar A, Phansopkar P, Gachake A, Mandhane K, Jain R, Vaidya S. A review on impact of lower extremity

- muscle length. *Journal of Pharmaceutical Research International* [Internet]. 2021 Jul 3;158–64. Available from: <https://doi.org/10.9734/jpri/2021/v33i35a31885>
- [16]. Karim R, Goel KD. Avascular necrosis of the hip in a 41-year-old male: a case study. *J Can Chiropr Assoc*. 2004 Jun;48(2):137-41. PMID: 17549225; PMCID: PMC1840046. Available on: <https://pubmed.ncbi.nlm.nih.gov/17549225/>
- [17]. Kariya G, Jawade S, Wadhokar OC, Kulkarni CA, Naqvi WM. Outcome of modified physiotherapy management in post-operative avascular necrosis managed by core decompression with PRP infiltration. *hip*. 2022;30(30°):45°.doi: 10.55522/jmpas.V11S1.1287
- [18]. Jagzape MV, Jain DP, Patil DS. Outcome of physiotherapy treatment on a 28-Year-Old male diagnosed with avascular necrosis. *Cureus* [Internet]. 2023 Nov 6; Available from: <https://doi.org/10.7759/cureus.48342>