

# Fractal Dimension and Lacunarity Detection of Mandibular Bone on Digital Panoramic Radiographs: A Potential Diagnostic Indicator for Osteoporosis in Smokeless Tobacco Chewers

Dr. Kadam Vishwas D<sup>1</sup>; Dr. Baride Preeti S<sup>2\*</sup>; Dr. Bansode Amruta<sup>3</sup>;  
Dr. Kale Lata<sup>4</sup>

<sup>1</sup> (PhD Scholar, PG Guide and Professor, Department of Oral Medicine and Radiology, Chhatrapati Shahu Maharaj Shikshan Santha's Dental College and Hospital, Chhatrapati Sambhajinagar (Aurangabad), Maharashtra, India)

<sup>2</sup> (PG Student, Department of Oral Medicine and Radiology, Chhatrapati Shahu Maharaj Shikshan Santha's Dental College and Hospital, Chhatrapati Sambhajinagar (Aurangabad), Maharashtra, India)

<sup>3</sup> (Reader, Department of Oral Medicine and Radiology, Chhatrapati Shahu Maharaj Shikshan Santha's Dental College and Hospital, Chhatrapati Sambhajinagar (Aurangabad), Maharashtra, India)

<sup>4</sup> (PhD & PG Guide, HOD and Dean, Department of Oral Medicine and Radiology, Chhatrapati Shahu Maharaj Shikshan Santha's Dental College and Hospital, Chhatrapati Sambhajinagar (Aurangabad), Maharashtra, India)

Correspondence Author: Dr. Baride Preeti S<sup>2\*</sup>

Publication Date: 2025/05/17

## Abstract

### ➤ *AIM –*

To use digital panoramic radiographs to assess/evaluate/study the fractal dimension and lacunarity trabecular pattern in mandibular bone to identify the early osteoporotic alterations in patients who chew smokeless tobacco and identify any differences compared to non-tobacco chewers.

### ➤ *Materials and Methods –*

90 digital OPG scans of completely dentulous patients between age 20 – 40 years were examined, out of which 45 patients with smokeless tobacco habit for more than 2 years and 45 were of healthy patients as control group. The mandibular trabecular bone's FD and lacunarity were evaluated using the ImageJ programme and the FracLac plugin on digital panoramic radiographs.

### ➤ *Settings and Designs –*

Prospective Cross Sectional Case Control Descriptive Observational Study, Department of Oral Medicine and Radiology.

### ➤ *Results –*

The differences between the research and control groups' mean FD values were statistically significant (P0.001). The case groups' mean FD was lower than the control groups, with SLTs having the lowest FD value. There was a significant difference in lacunarity between SLTs and controls (P0.001).

### ➤ *Conclusions –*

Differences in the values of FD & Lacunarity detected between the cases and controls, which discriminates texture differences of trabecular bone in SLT users. The analysis showed correlations with each other, detecting alterations in the trabecular pattern. Furthermore, it can be used as a practical, non-invasive method to assess osteoporotic changes in

**smokeless tobacco users during a routine examination for further management. Study with larger sample size should be done for more precise results.**

**Keywords;** *Fractal Dimension, Lacunarity, Mandible, Panoramic Radiography, Smokeless Tobacco.*

**How to Cite:** Dr. Kadam Vishwas D; Dr. Baride Preeti S; Dr. Bansode Amruta; Dr. Kale Lata (2025). Fractal Dimension and Lacunarity Detection of Mandibular Bone on Digital Panoramic Radiographs: A Potential Diagnostic Indicator for Osteoporosis in Smokeless Tobacco Chewers. *International Journal of Innovative Science and Research Technology*, 10(5), 401-407. <https://doi.org/10.38124/ijisrt/25May024>.

## I. INTRODUCTION

Osteoporosis is an infection characterized by decreased bone strength and expanded susceptibility to fractures secondary to a minor or no injury. The bone microarchitecture is changed in osteoporotic patients. Osteoporosis diminishes the thickness and number of trabeculae and increases trabecular partition. In this manner, it changes X-ray constriction in the bone and in this manner changes the thickness and surface of the picture <sup>(1)</sup>. Among the poisonous substances included in the etiology of osteoporosis, tobacco plays a major part and it is considered as possibly modifiable hazard calculate. These items are utilized beneath the misguided judgment that nicotine in this frame is safe, though, assimilation through verbal mucosa is quicker and more nicotine in lesser time is dumped into circulatory system compared to cigarettes driving to quicker addictive inclination <sup>(2)</sup>.

Panoramic radiography (PR) is highlighted in this setting since it is regularly conducted in the dental office; it is quick and low-cost and employments low-dose X-radiation <sup>(3)</sup>. In dentistry, numerous considers have explored the appropriateness of all-encompassing radiography in recognizing patients with bone mass lessening and chance for osteoporosis, permitting the dental practitioner to allude a persistent restorative assessment to show this hazard some time recently it causes a fracture <sup>(4)</sup>.

Risk variables for osteoporosis incorporate both smoking and smokeless forms of tobacco, which are found to be destructive to bone wellbeing through different components. Few thinks about have appeared that smoking does not influence bone mass <sup>(5)</sup>. The impacts of tobacco on the mandible recognized by the fractal examination, such as FD and lacunarity on digital panoramic radiographs, might offer assistance in the early acknowledgment of osteoporotic changes and encourage incite referral for bone thickness evaluation and advance management <sup>(6)</sup>.

## II. PATIENTS AND METHODS

### • Study Designs and Subjects –

Prospective Cross Sectional Case Control Descriptive Observational Study, Department of Oral Medicine and Radiology. Conducted between July 2023 to August 2023. Prior institutional ethical committee clearance was obtained. OPG scans of 90 Completely dentulous patients from age 20 - 50 yrs. were analysed. With 45 cases with habit of smokeless tobacco chewing for more than 2 years and 45 control group with no such habit. No evidence of pathology, trauma or surgery that could affect the position of the structures in the region of interest in mandible and no evidence of any fracture in the region of interest in mandible.

### • Imaging Technique –

All 90 OPG reports will be analysed. They will be exported to JPEG image format by using Digital Image and Communications in Medicine (DICOM) software. Imaging data was obtained using OPG SCANNER VATCEH MODEL PCH-2500.

### • Imaging Evaluation –

All OPGs were collectively assessed by using imageJ scanner programme. Region of interest is named by square shaped box of 168 x 168pixel size anterior to internal foramen (Figure 1). The named regions of interest were reused using the system designed by White and Rudolph. The ROIs were duplicated (Figure 2) and also blurred by a Gaussian sludge. The performing heavily blurred image was also subtracted from the original image. Bone marrow spaces and trabeculae were discerned from each other by adding a 128- slate value to each pixel position. The image was also binarized to outline bone gist spaces and trabeculae. The noise of the performing image was excluded with erosion, and the outlines of the structures were emphasized using dilation. The image was also reversed to make the trabeculae black and bone marrow spaces white. The cadaverous structure indicated the bone marrow pattern, and thenon-skeletal structure represented bone marrow in the skeletonized binary image (Figure 3). After skeletonization, the ROIs were prepared for evaluation of FD and lacunarity. FD was calculated using the box-counting system and Lacunarity was calculated using a plugin named FracLac. ImageJ (Figure 4) is a public domain software that facilitates image processing and analysis (ImageJ, National Institutes of Health, Bethesda, MD).

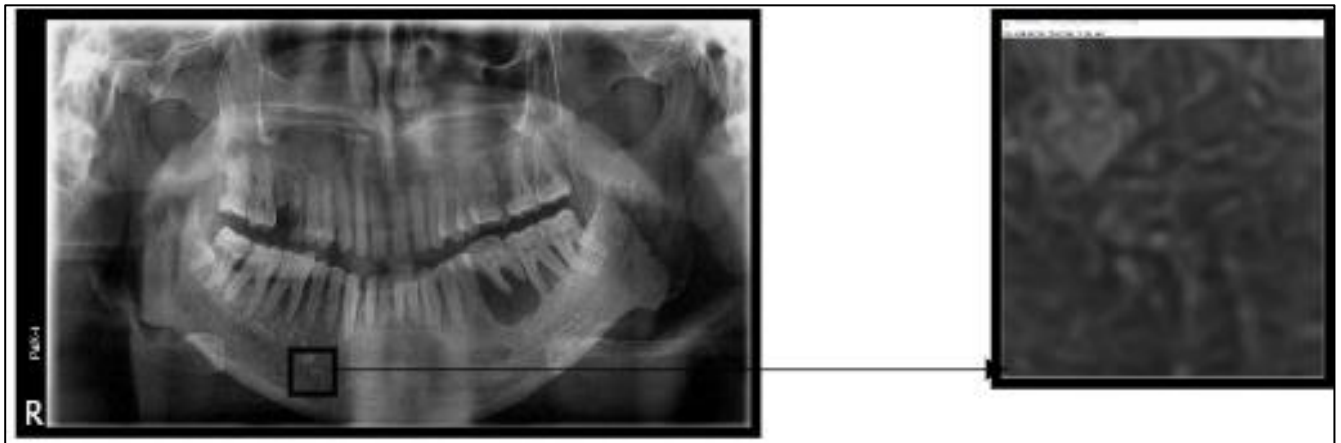

Fig 1 Selection of Region of Interest

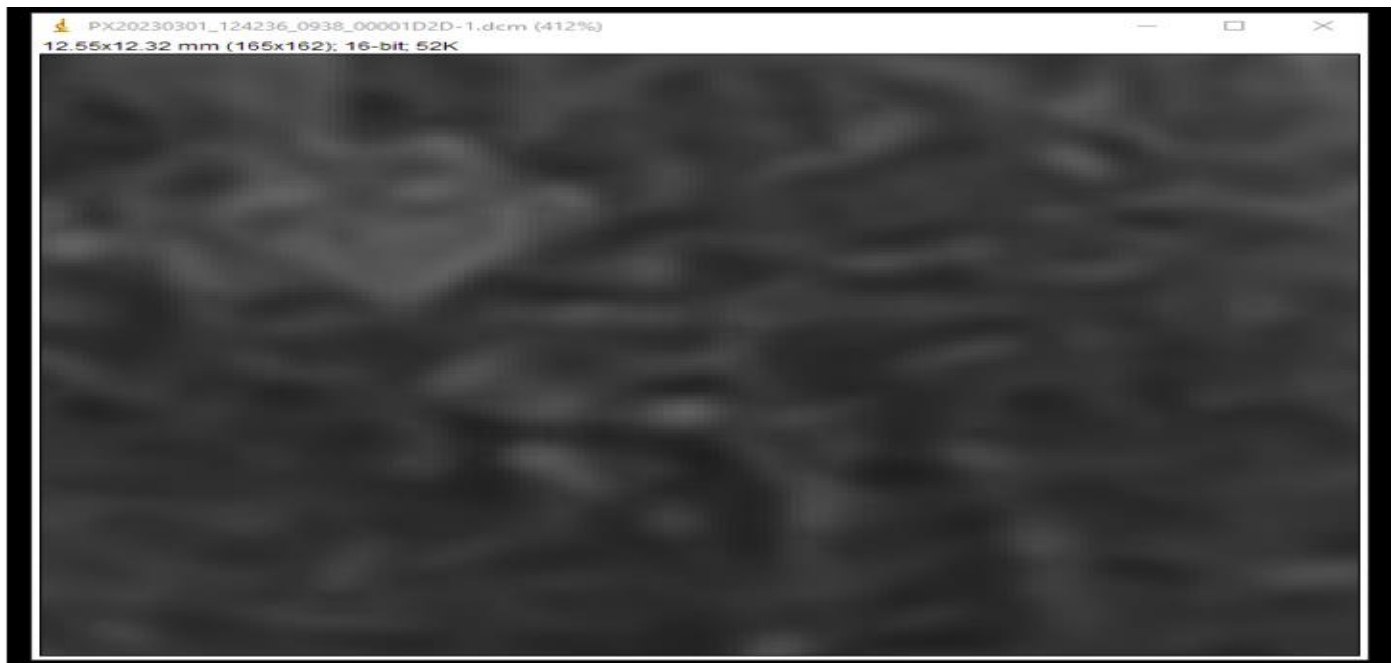

Fig 2 Duplication of ROI

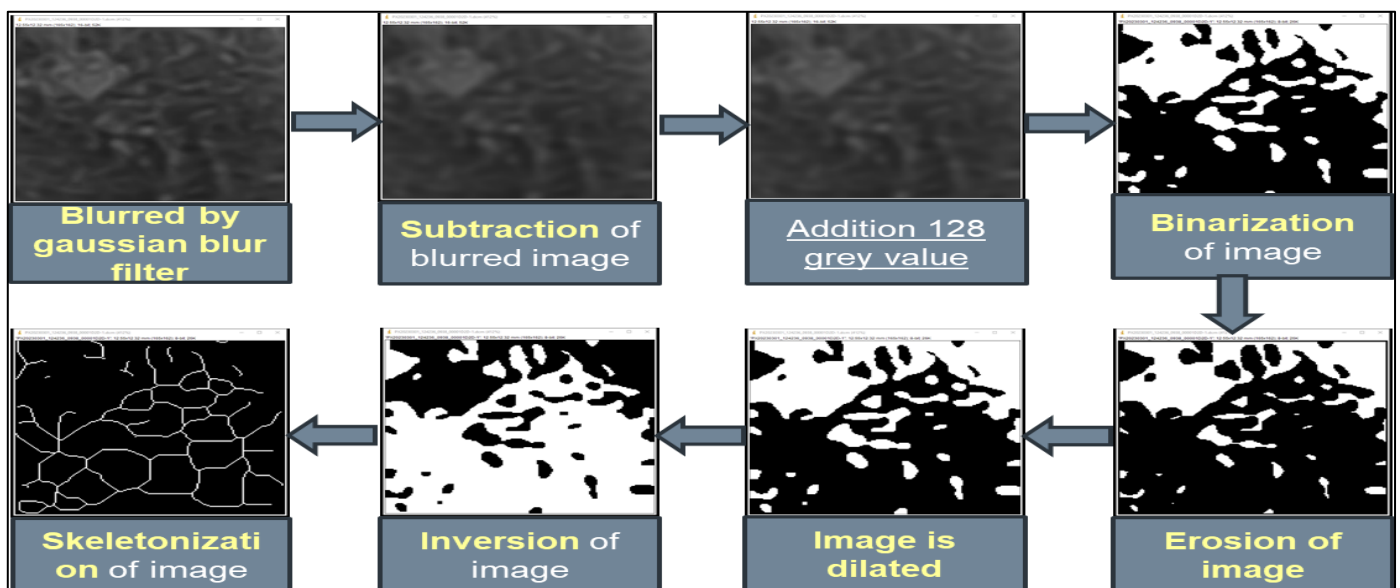


Fig 3 Processing Method

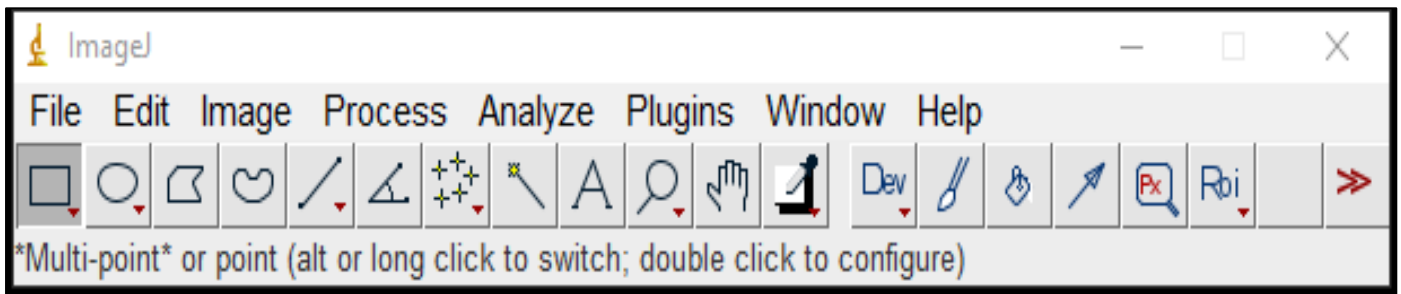


Fig 4 Image j Software

- *Statistical Analysis –*

Statistical analysis will be performed using Statistical Product and Service Solution (SPSS) version 21 for Windows (SPSSInc, Chicago, IL). Descriptive quantitative data will be expressed in mean and standard deviation respectively. Data normality will be checked by using Shapiro – Wilk test.

Confidence interval is set at 95% and probability of alpha error (level of significance) set at 5%. Power of the study set at 80%. Intergroup comparison between both groups in respect to study parameters will be done using unpaired t test.

### III. RESULTS

90 patients in the study were divided equally between two groups 45 were of cases group with habit of smokeless tobacco chewing for more than 2 years and 45 were of control group with no such habit. Mean age group for cases is 36.5 while for control group it is 37.04. Among cases 38 were males and 6 were females while in control group male count was 38 and female count was 6. There was no statistical significance seen in age group and gender group (Table 1 and 2). Mean fractal dimension of cases and control group is 1.44 and 1.5 respectively. Mean lacunarity of cases and control group is 0.279 and 0.264.(Table 3 and 4) The differences in the mean FD and mean lacunarity values of the cases and control groups were significant ( $P < 0.001$ ) which suggests highly significance.

Table 1 Comparison of Mean Age between Cases and Control Group  $**p > 0.05$ -no Statistical Significant Difference

	Mean	SD	SE	Unpaired t test	P value, Significance
Group A (Cases)	36.34	8.16	1.23	$t = -0.427$	$P = 0.671$ (NS)
Group B (Control)	37.04	7.3	1.1		

Table 2 Comparison of Gender between Cases and Control Group  $**p > 0.05$  - no Statistical Significant Difference

	Male N (%)	Female N (%)	Unpaired t test	P value, Significance
Group A (Cases)	38 (86.4%)	6 (13.6%)	$\chi^2 = 0.0$	$P = 1.000$ (NS)
Group B (Control)	38 (86.4%)	6 (13.6%)		



Table 3 Comparison of fractal dimension between cases and control group \*\*P&lt;0.001-highly statistical significant difference.

	Mean	SD	Mean Difference (SE)	Unpaired t test	P value, Significance
Group A (Cases)	1.44	0.04	0.057 (0.008)	t = -6.966	p < 0.001**
Group B (Control)	1.5	0.03			


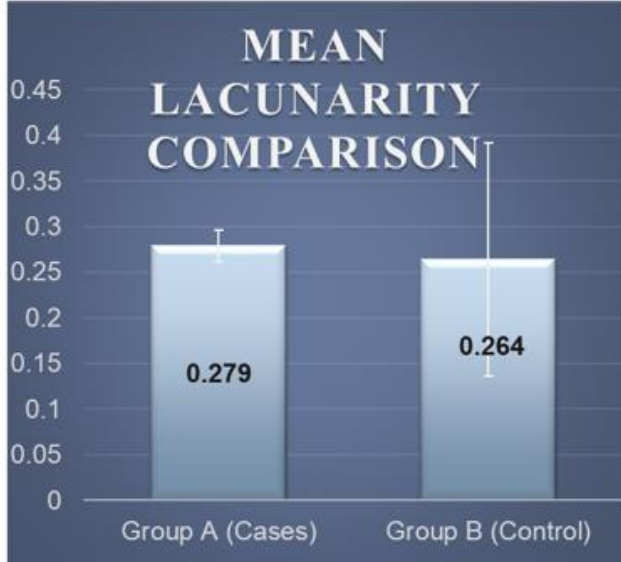


Table 4 Comparison of mean lacunarity between cases and control group \*\*p&lt;0.001-highly statistical difference

	Mean	SD	Mean Difference (SE)	Unpaired t test	P value, Significance
Group A (Cases)	0.279	0.017	0.0148 (0.0032)	t = 4.612	p < 0.001**
Group B (Control)	0.264	0.128			



#### IV. DISCUSSION

This study evaluated the fractal dimension (FD) and lacunarity from digital panoramic radiographs to assess trabecular bone changes in individuals with a history of smokeless tobacco use. The results demonstrate significant differences in trabecular bone microarchitecture between cases and controls, suggesting early osteoporotic changes in tobacco users.

##### ➤ Demographic Comparison:

The age and gender distribution between the case and control groups did not differ significantly ( $p = 0.671$  and  $p = 1.000$ , respectively), ensuring proper group comparability and minimizing confounding factors known to influence bone mineral density (BMD)<sup>(7)</sup>. This matching enhances the reliability of comparisons in fractal and lacunarity values.

##### ➤ Fractal Dimension and Lacunarity Analysis:

The mean FD was significantly lower in the case group ( $1.44 \pm 0.04$ ) compared to controls ( $1.50 \pm 0.03$ ) ( $p < 0.001$ ),

indicating reduced complexity and connectivity in the trabecular pattern of tobacco users. These findings align with previous studies showing that fractal analysis can detect early alterations in trabecular bone before they are evident in standard radiographs or densitometry<sup>(8,9)</sup>. White and Rudolph demonstrated similar reductions in mandibular FD in osteoporotic patients using panoramic images, supporting the method's diagnostic potential<sup>(10)</sup>.

Lacunarity, a measure of structural inhomogeneity, was significantly higher in cases ( $0.279 \pm 0.017$ ) than in controls ( $0.264 \pm 0.0128$ ) ( $p < 0.001$ ), suggesting increased spacing and irregularity in trabecular bone. Karperien et al. emphasized that a higher lacunarity value reflects a more porous, fragile bone network and correlates with fracture risk and impaired bone strength<sup>(11)</sup>.

Similar results were reported by Geraets et al., who noted that panoramic radiographs, when analyzed for FD, could predict low skeletal BMD with moderate accuracy,

emphasizing their utility as screening tools in dental settings<sup>(12)</sup>.

➤ **Relevance to Tobacco-Related Bone Loss:**

Tobacco constituents—especially nicotine and nitrosamines—have been shown to inhibit osteoblast activity, promote osteoclastogenesis, and impair calcium absorption, all of which contribute to reduced BMD and increased fracture susceptibility<sup>(13,14)</sup>. This study's findings are consistent with these pathophysiological mechanisms (Figure 5). The accompanying flowchart briefly outlines both direct

and indirect pathways by which tobacco use compromises bone health.

Multiple clinical studies also support the link between tobacco and bone deterioration. A meta-analysis by Ward and Klesges confirmed that tobacco use, including smokeless forms, is associated with significantly lower BMD and higher fracture incidence<sup>(15)</sup>. Furthermore, Dalli et al. demonstrated that chronic use of smokeless tobacco led to measurable decreases in bone turnover markers and BMD, particularly in younger males, reinforcing the relevance of early detection methods like those used in the current study<sup>(16)</sup>.

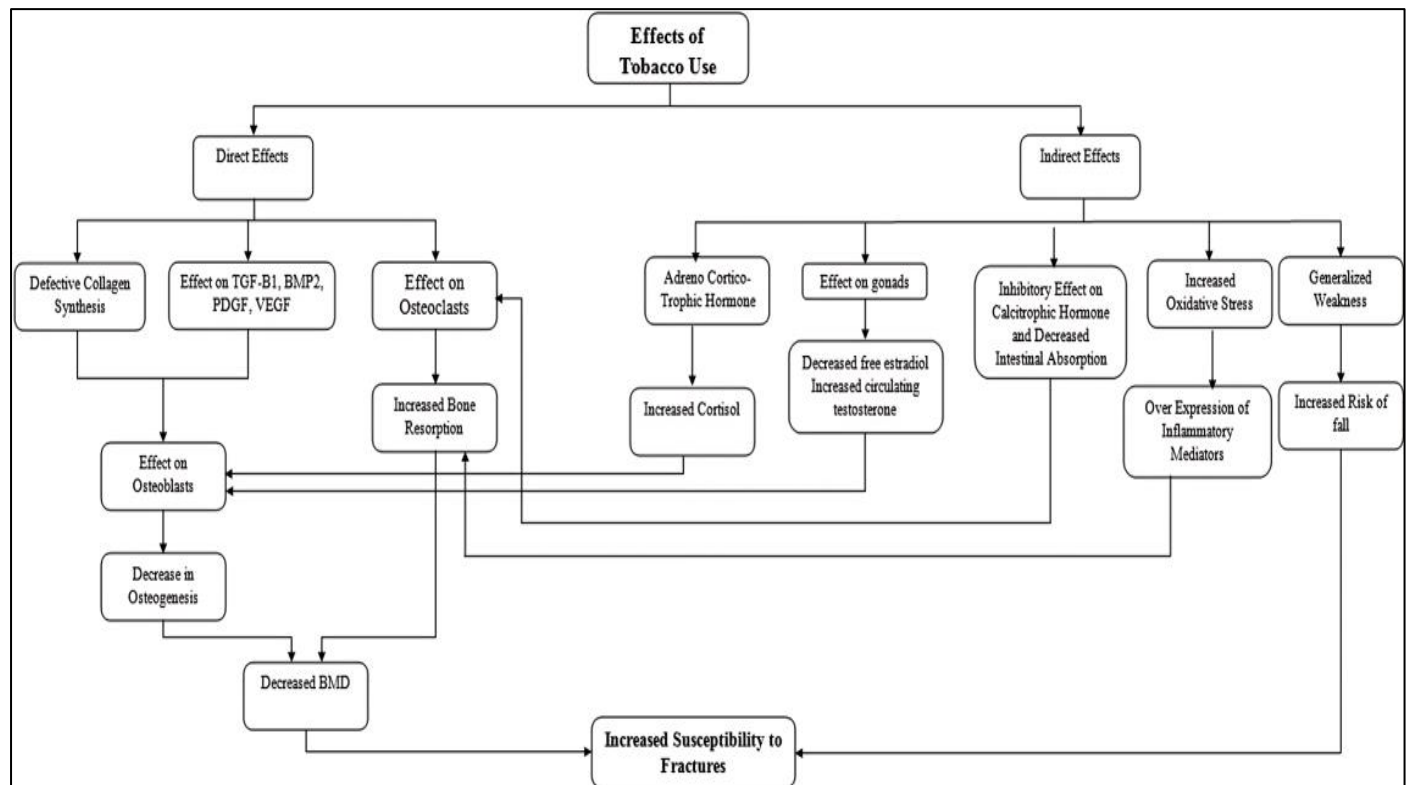


Fig 5 Pathophysiological mechanism of tobacco in causing decreased BMD

➤ **Clinical and Research Implications:**

These findings underscore the clinical utility of panoramic radiographs—commonly used in routine dental practice—as a screening modality for identifying individuals at risk of skeletal fragility due to smokeless tobacco use. Given the widespread availability and low cost of these imaging tools, their integration with fractal and lacunarity analysis could serve as an effective, non-invasive strategy for early detection and monitoring of bone changes.

Moreover, since osteoporosis is often asymptomatic until fracture, early identification of compromised bone architecture using panoramic imaging could enable timely referrals for confirmatory testing (e.g., DEXA) and preventive interventions. This approach is particularly relevant in resource-limited settings where access to advanced imaging may be restricted.

Future studies should investigate the longitudinal value of FD and lacunarity in predicting osteoporotic outcomes and assess whether tobacco cessation leads to microarchitectural

improvements. Additionally, correlations with systemic bone densitometry results would further validate panoramic-based metrics as surrogate markers for BMD.

## V. CONCLUSION

This study demonstrated that fractal dimension and lacunarity analysis of mandibular trabecular bone on digital panoramic radiographs can effectively differentiate between individuals who use smokeless tobacco and those who do not. Smokeless tobacco users exhibited a significant reduction in fractal complexity and an increase in trabecular irregularity, suggesting early osteoporotic alterations.

The use of these image analysis techniques provides a practical, non-invasive method for preliminary assessment of bone quality, particularly in dental settings where panoramic radiographs are routinely employed. These findings support the integration of fractal and lacunarity evaluations into dental radiographic assessments to identify patients at risk of systemic bone loss.

However, to enhance the reliability and clinical applicability of these observations, further research with larger sample sizes and correlation with DEXA measurements is recommended

## REFERENCES

- [1]. Sindeaux R, Figueiredo PT, de Melo NS, Guimarães AT, Lazarte L, Pereira FB, de Paula AP, Leite AF. Fractal dimension and mandibular cortical width in normal and osteoporotic men and women. *Maturitas*. 2014 Feb;77(2):142-8. doi: 10.1016/j.maturitas.2013.10.011. Epub 2013 Nov 4. PMID: 24289895.
- [2]. Syed Sohail Abbas, Saeeda Baig, Qamar Jamal, Hasan Danish, Syeda Abia Ambe. Volume: 3, Issue: 3, 15-18 March 2015 *European Journal of Biotechnology and Bioscience* ISSN: 2321-9122 Impact Factor: 3.742
- [3]. Camargo, A.J., Côrtes, A.R.G., Aoki, E.M., Baladi, M.G., Arita, E.S. and Watanabe, P.C.A. (2016) Analysis of Bone Quality on Panoramic Radiograph in Osteoporosis Research by Fractal Dimension. *Applied Mathematics*, 7,375-386.
- [4]. Tavares KNP, Mesquita RA, Amara PTM, Brasileiro CB (2016) Predictors Factors of Low Bone Mineral Density in Dental Panoramic Radiographs. *J Osteopor Phys Act* 4: 170. doi:10.4172/2329-9509.1000170.
- [5]. Suman B, Redhu A. Relationship of bone mineral density with panoramic radiomorphometric indices in tobacco users in India. *J Indian Acad Oral Med Radiol* 2020;32:119-26.
- [6]. Basavarajappa et al, J Dent Res Dent Clin Dent Prospects, Fractal dimension and lacunarity analysis of mandibular bone on digital panoramic radiographs of tobacco users 2021,15(2), 140-146 doi: 10.34172/joddd.2021.024 <https://joddd.tbzmed.ac.ir>
- [7]. Altman DG, Bland JM. Matching. *BMJ*. 1994;309(6962):1128.
- [8]. Geraets WG, van der Stelt PF. Fractal properties of bone. *Dentomaxillofac Radiol*. 2000;29(3):144–53.
- [9]. Southard KA, Southard TE, Krizan KE, Hillis SL. Fractal dimension analysis of mandibular trabecular bone in diabetes. *Oral Surg Oral Med Oral Pathol Oral Radiol Endod*. 2000;89(4):532–8.
- [10]. White SC, Rudolph DJ. Alterations of trabecular bone pattern in patients with osteoporosis. *Oral Surg Oral Med Oral Pathol Oral Radiol Endod*. 1999;88(5):628–35.
- [11]. Karperien A, Ahammer H, Jelinek HF. Quantitating the subtleties of microglial morphology with fractal analysis. *Front Cell Neurosci*. 2011;5:62.
- [12]. Geraets WG, van der Stelt PF, Netelenbos JC, Elders PJ. A new method for measuring BMD using dental radiographs. *J Bone Miner Res*. 1990;5(6):653–8.
- [13]. Holliday R, Moore A, Ashrafian H. Smoking and bone health. *BMJ*. 2001;323(7320):1111.
- [14]. Jones G, Nguyen T, Sambrook PN, Kelly PJ, Eisman JA. Progressive loss of bone in postmenopausal women: Impact of smoking. *J Clin Endocrinol Metab*. 1994;79(2):404–7.
- [15]. Ward KD, Klesges RC. A meta-analysis of the effects of cigarette smoking on bone mineral density. *Calcif Tissue Int*. 2001;68(5):259–70.
- [16]. Dalli M, Atici MY, Bagci N, et al. Effects of smokeless tobacco on bone turnover and BMD. *J Bone Miner Metab*. 2021;39(1):129–35.